

MODULE 4

ORGANS and SYSTEMS

DRAWING 55: THE LYMPHATIC SYSTEM

The word “lymph” comes from the name of a Roman goddess of water, Lymph, so we can guess that lymph must have some connection with water. In fact, it is mostly water. Lymph is what you get when blood plasma (which is mostly water) leaks out of blood vessels. Sometimes the vessels leak a little (under normal conditions) and sometimes they leak a lot (like when histamine is present). About 90 percent of the fluid makes its way back into the bloodstream again, but about 10 percent does not. The physics of blood pressure (the pressure of osmosis pushing in toward the vessel) causes most of the water to migrate back in. However, the fact that a small amount of fluid can’t get back in is anything but a design flaw. Rather, it is a very clever mechanism crucial for the proper functioning of the immune system.

After the plasma leaks out into the interstitial space between cells, its name is changed to **lymph**. The lymph will contain small proteins, waste products from the cells, and also perhaps some viruses or bacteria. Some filtering, cleaning, and recycling needs to be done. This will be accomplished by the lymphatic system. The entry into the lymphatic system is a network of billions of tiny lymph vessels, sometimes called lymph capillaries. The lymph capillaries are found anywhere you find blood capillaries. Unlike blood capillaries, the lymph vessels don’t form loops. Blood vessels are basically a closed system, with a continuous circular pattern inside of which the blood flows round and round and round.

Lymph capillaries have a definite starting point. The tip of a lymph vessel is made of a single layer of flat (squamous) epithelial cells that have spaces between them large enough for not only lymph fluid to enter, but all the “junk,” too. The lymph vessels also allow entry of immune cells such as macrophages. As the fluid travels down the lymph vessels, it passes through one-way valves (made by epithelial cells). The valves keep the fluid from flowing backwards. The lymph system does not have a pump like the blood circulatory system does (the heart) so keeping the fluid moving has to be accomplished in other ways. The general movement of your muscles throughout the day helps to push the lymph fluid along. Also, though this is a little hard to understand, the pressure difference created by flowing blood at the place where the lymph dumps into the bloodstream also helps to draw the lymph in the proper direction. People with inadequate lymph circulation often get massages to help push the lymph along.

At various points in the body, the lymph vessels must pass through **lymph nodes**. These are filtering centers where the lymph fluid is cleaned up. We will study them in more detail in the next lesson. Groups of nodes are located near joints, in the groin area, in the chest, and in the neck. The **spleen** also functions very much like a lymph node, too, as we will see in the next lesson. Lymph nodes respond to pathogens (viruses and bacteria) and sometimes get a little larger while you are fighting an infection. The nodes can enlarge very quickly, but may take weeks or even months to get back down to their original size.

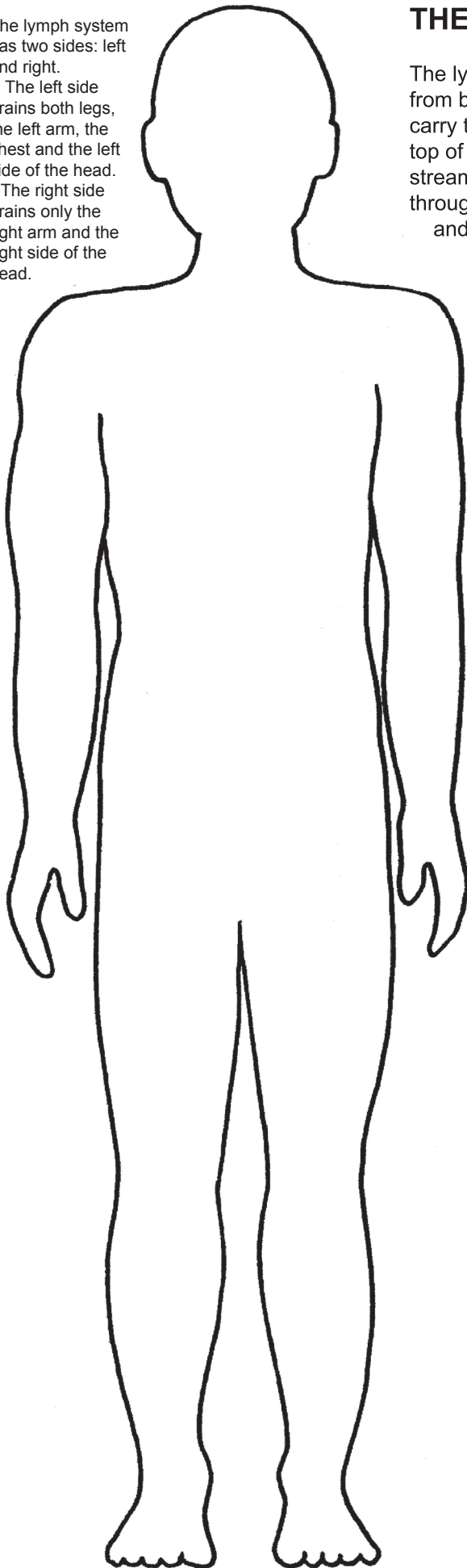
Microscopic lymph vessels connect to slight larger vessels, which connect to even larger ones, and eventually they all merge together into visible vessels called ducts. The lymphatic ducts will reach their end at the place where they connect to a large vein on the side of the heart. This vein is located underneath the **collar bone**, or **clavicle**, so the vein is sometimes referred to as a **subclavicle vein**. As already mentioned, the action of the lymph fluid dumping into a quickly moving bloodstream is one of the factors that helps to draw the lymph fluid through the lymph system. (As a general rule, lymph is traveling upwards, fighting gravity, which is no mean feat considering that there is no pumping mechanism involved!) After having been through all those nodes, the lymph fluid should be clean and germ-free at this point, so dumping into the blood is not a problem. When it re-enters the blood, its name is changed back to “plasma.”

The lymphatic system has other filtering centers, besides the nodes and the spleen. These include the tonsils, the adenoids (up higher than the tonsils), the **appendix** and the **thymus**. We met the thymus in our study of immune cells. It is where T cells go to mature. The thymus is very large during childhood, then shrinks during teen years and is very small during adulthood. The appendix is located on the end of the colon, at a place where there is an extra pouch called the **cecum**. Both the cecum and the appendix appear to be storage areas for good bacteria that are helpful to the intestines. People used to think the appendix was basically useless. Now we know that it is a protected area where good bacteria can survive even through a bout of intestinal disease or infection that wipes out most of the other bacteria. The bacteria in the appendix can then come out and re-populate the intestines.

The lymph system has two sides: left and right.

-- The left side drains both legs, the left arm, the chest and the left side of the head.

--The right side drains only the right arm and the right side of the head.



The lymph system is made of a network of vessels that drain extra fluid from body tissues (the interstitial spaces between cells) into vessels that carry the fluid through lymph nodes and then up (against gravity!) to the top of the rib cage where lymph vessels dump the fluid back into the blood-stream. As the fluid makes its way up through the lymph vessels, it passes through lymph nodes where lymphocytes and macrophages can recognize and/or destroy any pathogens in the fluid. Also, macrophages and dendritic cells from the tissues can intentionally hop into the lymph vessels and drift to the nearest nodes so that they can present their antigens to T cells.

Lymph vessels have one-way valves so that the fluid can't go backwards. The fluid is pushed along through the vessels simply by the motion of our muscles as we go about our daily routines.

56: LYMPH NODES and the SPLEEN

Lymph nodes perform two main functions. They serve as filtering centers where lymph fluid is cleaned, and they also act a bit like army command centers where soldiers from the battlefield can relay information to officers who are in charge of making battle plans and sending out troops. The body has thousands of lymph nodes, ranging in size from a millimeter (the size of this dot .) to 2 cm (the size of a marble).

The shape of a node is very similar to a red kidney bean or a white navy bean. In fact, lymph nodes even share an anatomical feature with a bean: both nodes and beans have an area called the **hilum**. (“Hilum” means “little thing” in Greek.) The hilum on a bean seed is the scar where the seed used to be attached to the wall of the ovary. In a lymph node, the hilum is where the efferent lymph vessels come out and where the blood vessels go in and out. The spleen also has a hilum.

Lymph nodes are wrapped in a “bag” made of connective tissue. Every muscle, vessel, and organ in the body is wrapped in a thin coating of connective tissue. These “bags” can attach to each other to keep the organs tightly in place. The “bag” around a lymph node is called the **capsule**. The inside of a node is divided into compartments. The walls between the compartments are called **trabeculae** (*trah-BECK-cue-lae*), a word we saw back in lesson 36 when we learned about bone marrow making blood cells. The walls of the compartments in bone are also called trabeculae. Each compartment in a lymph node has a core called the **follicle**. Each follicle has a central area called the **germinal center**. The node is also divided into regions according to distance away from the hilum. The area farthest away from the hilum is the **cortex**. The area just inside of that is the **Paracortex**. (“Para” means “beside.”) The area closest to the hilum is the **medulla**. The words follicle, cortex and medulla, are very common words in anatomy and we’ll see them again soon.

Afferent lymph vessels bring lymph fluid from the tissues into the node. (“Afferent” comes from the Greek word roots “ad,” meaning “towards,” and “fer” meaning “to bring.”) A node will have about 4 to 10 afferent vessels feeding into it. The afferent vessels enter one of the compartments in the node, and the lymph fluid then flows into the node and around the follicle. In this space around the follicle there are many **reticular fibers**, just like the ones we saw in the loose (areolar) connective tissue. (Remember, “rete” means “net” or “network.”) Those reticular fibers act like a scaffolding for immune cells to crawl around on. This area is packed with macrophages and dendritic cells who try eat anything and everything that comes into the node. The macrophages and dendritic cells then present antigens (display pieces of what they ate) to the nearby T cells who live in the outer layer of the follicle. (The T cells matured in the thymus and then came to live in these T cell neighborhoods in the lymph follicles.) The central area of a follicle, the **germinal center**, is where B cells live. The T cells can go over and “talk” to the B cells when they need to. If the T cells have interacted with an APC (antigen presenting cell) they will try to find a B cell that matches that antigen. Remember, as a general rule, B cells can’t do anything without permission from the T cells. If a T cell activates a B cell, the B cell will then become a **plasma cell** and will start cranking out antibodies. The antibodies will leave the node through the capillaries or the efferent vessels. Either way, the antibodies will end up in the blood, and the blood will take them to all parts of the body.

A lymph node has blood vessels that come in at the hilum, right near the efferent (exit) lymph vessels. An arteriole (coming from the heart and carrying oxygen) goes into each follicle, then spreads out into tiny capillaries that collectively are called a **capillary bed**. The other side of the capillary bed is drawn in blue, since by that time most of the oxygen has been used up. When these capillaries get a bit larger they are called venules. The venules join together to form a larger vein that exits at the hilum. Some of the blood vessels in a lymph node are a very special kind: High Endothelial Vessels, or HEVs. These capillaries are made of very thick (“high”) endothelial cells, not flat ones like we find in regular capillaries. The thickness of the cells somehow makes it easier for lymphocytes, especially T cells, to pass through. This is the main way that T cells get into lymph nodes. It’s not all that important to remember this term (HEV) unless, of course, you are studying to be a doctor or nurse and need to pass an exam. More important is to understand that you find specialized structures in exactly the places they are needed. The body exhibits brilliant design.

The spleen is very much like a lymph node in some ways, so much of our learning about nodes will carry over to the spleen. The spleen is wrapped in a connective tissue capsule, it has a hilum, and it contains many of the same immune cells. One obvious difference is that the spleen does not have any lymph vessels going in or coming out. Only blood enters the spleen. The spleen sits to the left of your stomach (from your viewpoint) and right under the diaphragm. It is attached to these organs with connective tissue.

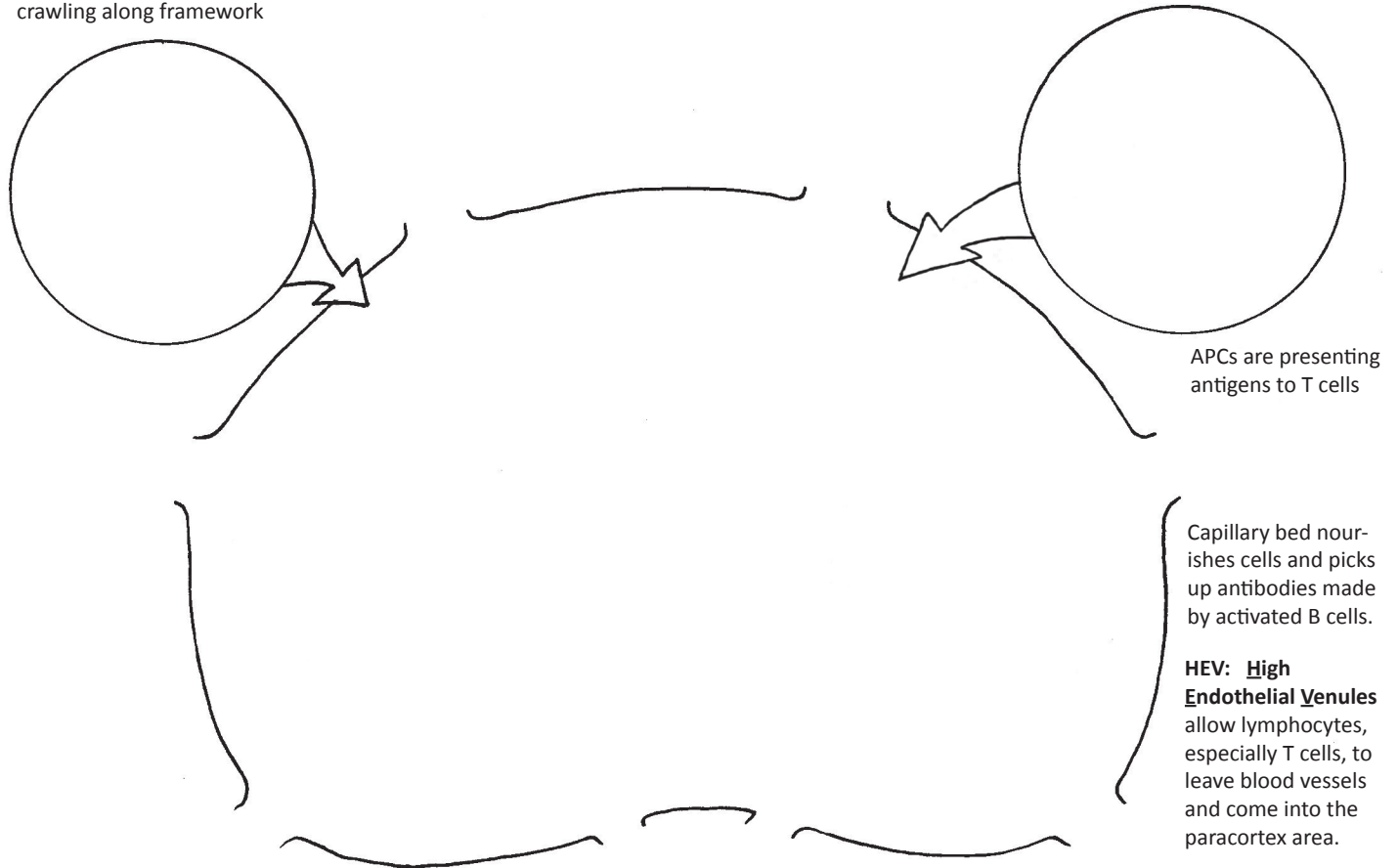
The spleen has two notably different sections called the **red pulp** and the **white pulp**. The white pulp is the tissue that is like a lymph node. White pulp is found wrapped around the lower portions of the blood vessels. In the white pulp we find many T cells, macrophages, and **follicles** containing B cells. We find the same processes going on here, with APCs presenting antigens to T cells, and T cells activating B cells. Additionally, we find something a bit different going on with the B cells in the follicles. Here, the B cells can act like APCs, presenting antigens to T cells. (“Rules” in biology rarely are without exception. Most of the time B cells sit there naive until a T cell activates them, but here in the spleen follicles, we see them playing a different role. It is possible that this goes on at other places in the body, too.) Since there are no lymph vessels going in and out of the spleen, immune cells wanting to come and go from the spleen must use the blood vessels.

The red pulp results from another exception to a rule. The circulatory system (the entire network of blood vessels) is a “closed” system. We mentioned this in the last lesson when we saw that the lymph system is not closed, but has many open-ended vessels where lymph enters. Here in the spleen, we find the one place where arterioles come to an end and let blood leak out. The red pulp is red because it is filled with loose blood cells. These loose red blood cells can only get into the venules that will put them back in circulation if they are healthy and have a normal shape. Diseased and damaged red cells will not be able to return to circulation and will be eaten by macrophages. Because there are so many red cells floating around in the spleen, it also functions as a storage area for an emergency supply of extra red cells. If you have sudden blood loss, your spleen can release some extra cells.

Reticular fibers with macrophages and dendritic cells crawling along framework

LYMPH NODE

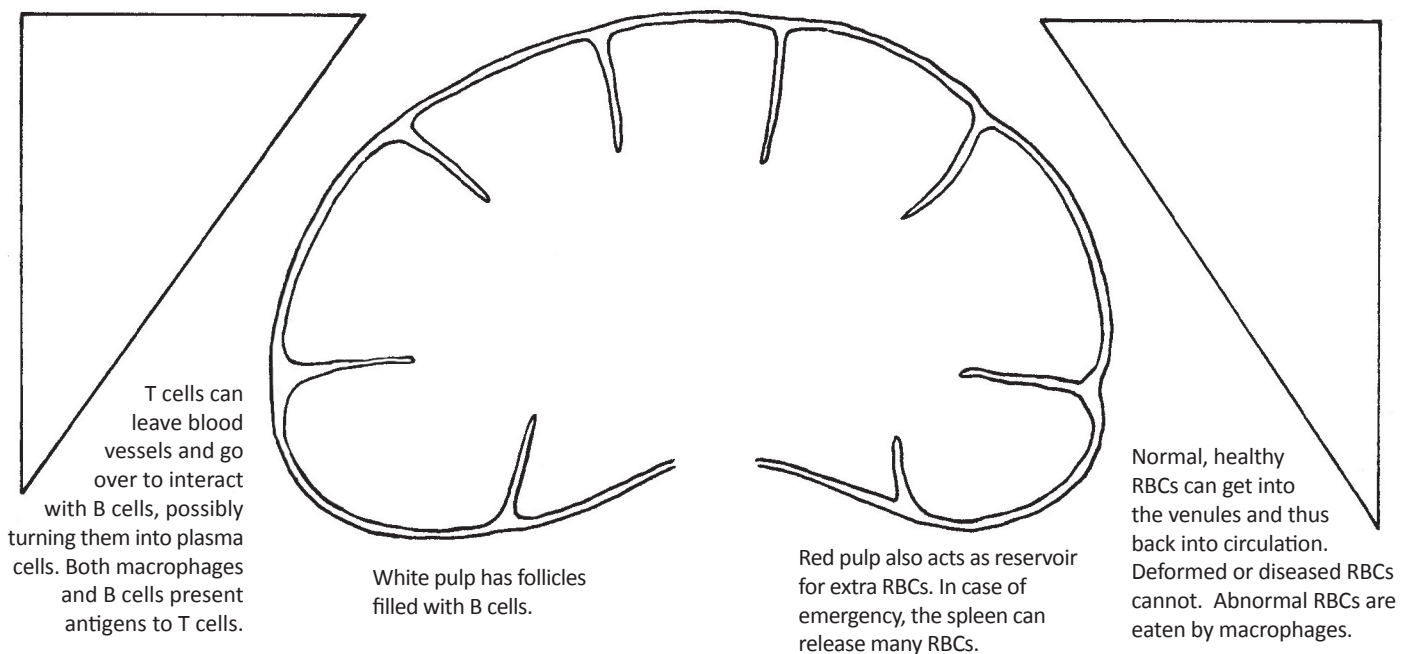
Naive B cells (can be activated by T cells and turn into plasma cells)



SPLEEN

WHITE PULP

RED PULP



57: SKIN

We don't usually think of the skin as an organ of the body, but it is actually the largest organ of our body. Organs are made of tissues, and here in the skin we will see all four tissue types, and a surprising number of connective tissue types (loose, irregular, adipose, blood, lymph).

The skin can be divided into basically three layers: **epidermis, dermis, hypodermis**. "Dermis" is Greek for "skin." The epidermis came from that blue layer we learned about in embryology, the ectoderm. The dermis came from the red layer, the mesoderm. You'd never guess that these two layers came from completely different embryonic sources. The basement membrane is the "dividing line" between the these layers. Remember, the basement membrane is always the bottom layer of epithelial tissue.

The epidermis is made of stacks and stacks of epithelial cells. The bottom layer is called the **basal layer** and it is the only truly active layer. This is the only place in the epidermis that mitosis occurs. Most of the cells in the basal layers are keratinocytes. These cells produce **keratin**, a waxy chemical that gives skin its waterproof qualities. As keratinocytes multiply, the old cells get pushed up. More cells pile up underneath and eventually the old cells get pushed to the surface. On their way up they begin to die. Organelles start to disappear until finally the cells are nothing but empty shells filled with waxy keratin. The surface of our skin is dead cells, millions of which fall off every day. (Microscopic creatures called dust mites love to eat cells that fall off our skin, which is why they like to live in pillows and blankets. Yes, your pillow is probably inhabited by tiny spider-like creatures!)

The very top layer of the epidermis is called the **stratum corneum**. ("Stratum" means "layer," and "corneum," means "hard and waxy.") There are other sub-layers with hard-to-remember names, but they are of minor importance in our overview, so we'll just skip them. If you want to know more, just Google "epidermis layers."

There is only one type of immune cell in the epidermis. We first learned about it back in the lesson on macrophages. It is called a **Langerhans cell**, and it is similar to a macrophage. It moves about, looking for germs or dirt particles. It is the first line of defense up there in the top layer of skin. There is one Langerhans cell for every three dozen keratinocytes.

The basal layer of the epidermis is where you will find **melanocytes**. Melanocytes produce a pigment called **melanin**. ("Melano" is Greek for "black, or dark.") Melanin is what gives color to our skin and hair. The melanocytes make the melanin molecules and package them into vesicles that are exported out of the cell into the surrounding area. The nearby keratinocytes pick up these vesicles and bring them inside. The dendritic shape of the melanocytes helps in the distribution of the vesicles.

There are basically two types of melanin: brown and red. If you've ever seen a tiny red mole on someone's skin, you are seeing the red kind. Brown is the color we are more familiar with. People who have dark brown skin have very active melanocytes. People with light skin have melanocytes that don't produce much melanin. Melanocytes can be encouraged to produce more melanin if exposed to sunlight. This is what causes a suntan. It's important to note that everyone has approximately the same number of melanocytes in their skin. The difference between dark and light skin is how active these cells are. Again, the **ONLY** difference between dark and light skin is the activity level of the melanocytes. Melanin acts as a natural sunscreen. It "catches" ultraviolet rays from the sun that can damage DNA and destroy Langerhans cells. Sunlight is not all bad, however, as it also seems to stimulate the production of vitamin D. Your body must process vitamin D in order to make it usable by all body cells, and the epidermis of the skin is the primary site for this.

When cell growth in the basal layer gets out of control and too much mitosis happens (because of a mutation), this can result in skin cancer. When a keratinocyte mutates and becomes cancerous we call this basal cell carcinoma (or squamous cell carcinoma). When a melanocytes mutates it causes melanoma. Melanoma is the kind that is more likely to spread to other parts of the body.

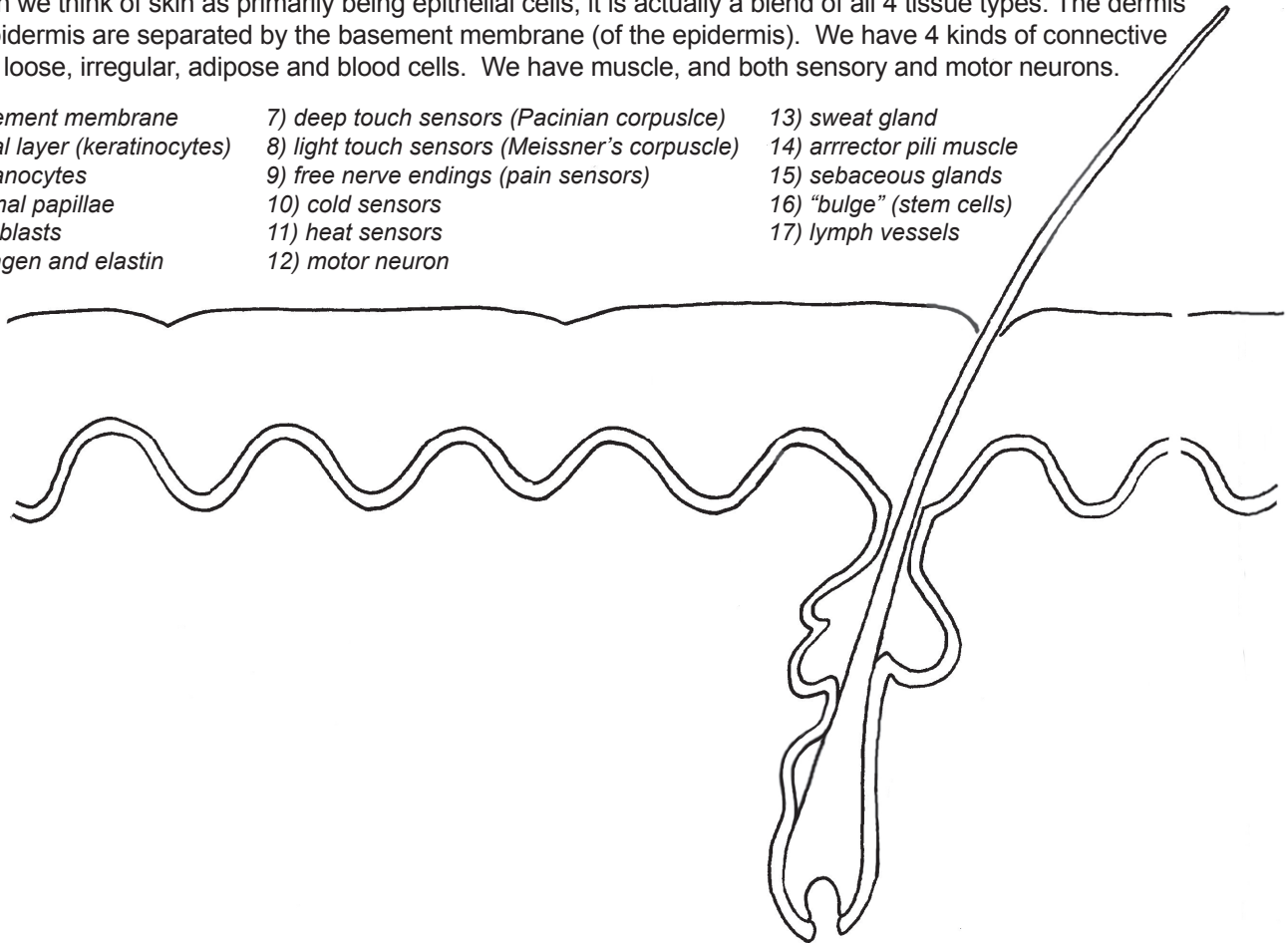
The dermis is full of things we've already studied. The top part of the dermis is loose (areolar) connective tissue and the lower part is dense irregular tissue. These connective tissues are filled with fibroblasts that are making collagen, elastin and reticular fibers. There are many immune cells roaming about, such as macrophages and lymphocytes (T and B cells). The dermis also has a rich blood supply. Did you notice that the epidermis has no capillaries? This is a very good design because you wouldn't want to be bleeding every time your skin brushed against something. The damage has to go down to the dermis before blood appears. The dermis also has lymph capillaries, not just blood capillaries. As we learned in the lymph lesson, lymph vessels are open at the ends, not closed like blood capillaries. The lymph vessels recycle the fluid between the cells (interstitial fluid) and remove all the waste products that leak out of the cells into this space.

The dermis also contains hair follicles. We'll learn more about them in the next lesson. The hair is associated with sebaceous glands that produce oily **sebum** that keeps our skin soft and helps it to be water resistant. (Too much sebum on our scalp and we feel the need for a shampoo!) Each hair has a tiny muscle, called the **arrector pili**, that can pull it up straight. ("Arrector" means "stands up straight" and "pili" means "hair.") When the hair goes up straight, the skin bunches together at the top of the follicle and forms what most of us call a "goose bump." Geese (or chickens or turkeys) that are plucked and ready for the oven are covered with little bumps at the places where the feathers were plucked out.

What students usually find most interesting about the dermis are all the strange-looking nerves. There are sensors for pain, light touch, deep touch, hold and cold. The deep touch sensors called Pacinian corpuscles (*CORE-puss-uhs*) are dendrites that will start action potentials when stimulated by touch. The ends of the dendrites are surrounded by protective "padding" that helps them not be too sensitive. There are light touch sensors called Meissner's corpuscles. Hot and cold nerve endings are triggered by temperature. We have these hot and cold nerves on our tongue, too and they can be mistakenly triggered by the chemicals in some foods. Nerve endings also surround the hairs, giving the nervous some feedback about what is happening to the hairs. We've already learned a bit about the function of these neurons, and we know that they are afferent nerves, taking signals from the body to the central nervous system (spine and brain). There are efferent (motor) neurons connected to the tiny muscle that moves the hair.

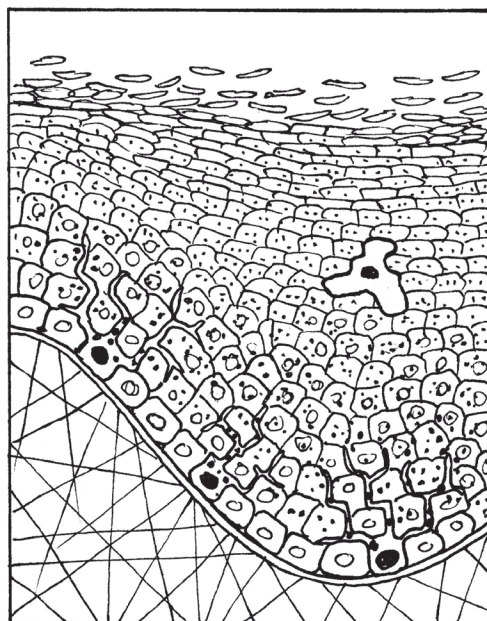
Though we think of skin as primarily being epithelial cells, it is actually a blend of all 4 tissue types. The dermis and epidermis are separated by the basement membrane (of the epidermis). We have 4 kinds of connective tissue: loose, irregular, adipose and blood cells. We have muscle, and both sensory and motor neurons.

- | | | |
|--------------------------------|---|--------------------------|
| 1) basement membrane | 7) deep touch sensors (Pacinian corpuscle) | 13) sweat gland |
| 2) basal layer (keratinocytes) | 8) light touch sensors (Meissner's corpuscle) | 14) arrector pili muscle |
| 3) melanocytes | 9) free nerve endings (pain sensors) | 15) sebaceous glands |
| 4) dermal papillae | 10) cold sensors | 16) "bulge" (stem cells) |
| 5) fibroblasts | 11) heat sensors | 17) lymph vessels |
| 6) collagen and elastin | 12) motor neuron | |



THE EPIDERMIS is made of mostly **keratinocytes**. The keratinocytes in the basal layer are the only ones that go through mitosis. As they divide, the new cells go upwards. As the cells mature, they begin producing a lot of a waxy protein called **keratin** and they also begin to lose their organelles. By the time they reach the top, they have lost everything, even their nucleus. They are dead cells filled with keratin. We have these dead cells flaking off our skin all the time.

FIBROBLASTS
COLLAGEN AND ELASTIN



Top layer of dead cells is called the **STRATUM CORNEUM**

KERATINOCYTES: all cells except melanocytes and Langerhans cells

LANGERHANS cells are a type of macrophage and are the only immune cells in the epidermis.

MELANOCYTES produced the pigment **melanin**. Melanin is brown or red (usually brown). Dark skin has more melanin than light skin. Melanocytes release the melanin in little vesicles and these vesicles are taken in by keratinocytes.

BASAL LAYER (of keratinocytes)

BASEMENT MEMBRANE

58: HAIR and NAILS

Hair and nails are considered to be “accessories” of the skin. They are produced by the same type of cells that make skin, so they really are part of the skin, specifically the epidermis. The skin with all its accessories is called the **integumentary system**.

To understand how hair and nails form, we need to review how the epidermis works. As with all epithelial tissue, there is basement membrane on the bottom, with its network of collagen fibers that can bond to tissue beneath. Above the basement membrane we find the basal layer of cells, which act a bit like stem cells. (In fact, some texts will call them stem cells.) These basal cells go through mitosis constantly. A few daughter cells will stay there on the bottom in the basal layer, but most daughter cells will gradually be pushed higher and higher as more cells keep accumulating beneath them. As they rise, two things happen. First, they begin to produce large volumes of the protein **keratin**. Keratin is strong as well as water-resistant, and gives skin these two properties. Second, when the cells are almost full of keratin, the organelles begin to disintegrate and disappear. By the time the cells are close to the top, even the nucleus is gone. The keratinocyte is technically “dead” at that point.

An interesting side note at this point is that right before a keratinocyte dies, it produces enzymes that are capable of chewing through the desmosomes that hold the cells together. If this does not happen, the dead skin cells at the surface will not be able to flake off. Might not sound like a big deal, but it is. People who have a genetic mutation in the genes for producing these enzymes will have a horrible skin condition that causes them much suffering. They must bathe and scrub and scrape their skin daily to try to peel off the dead cells. It’s inconvenient and painful.

Hair and nails are also made of keratinocytes that are being pushed up, filling with keratin, and then dying. However, the keratinocytes in the hair and nails know not to make these destructive enzymes before they die. We really don’t want our hair and nails flaking apart. Somehow, these keratinocytes know that they are located not in the skin but in hair and nails and they alter their behavior accordingly. The hair shaft has a central core called the **medulla**, a colored **cortex**, and a clear outer layer called the **cuticle**. All of these words are common science words. “Medulla” means “middle,” “cortex” means “outer layer,” and “cuticle” means “skin.”

A hair follicle is basically a bit of epidermis that got pushed down into the dermis. Imagine the epidermis as a piece of stretchy fabric lying on a pan of jello. Put a finger on the fabric, then poke it down as far as your finger will go. You’ve just created a hair follicle. The inside of the hair follicle is epidermis. (If you look back at your drawing or model of the skin, you will see that this is so). The epidermal cells keep track of where they are in the follicle, though, and the ones on the sides behave differently than the ones at the bottom. The cells at the very bottom are extremely active and they are the ones that generate the hair. You will also find some melanocytes mixed in with the epidermal cells at the bottom of the follicle. Interestingly, melanocytes are not made by the basal cells. Keratinocytes don’t differentiate into melanocytes. Melanocytes originated in the neural crest region of the one-week-old embryo. As the embryo developed skin, the melanocytes traveled throughout the body, then lodged in skin and in hair follicles.

At the bottom of the follicle, there is a tall bump where the dermis pokes up into it. This is called the **dermal papilla**. The dermis is where the blood supply is, so the dermal tissue must supply blood to the fast-growing basal cells. The active basal cells form a curve around the top of the papilla. As they go through rapid mitosis, they will create a bulge of cells called the **hair bulb**. A similar process to what happens in the skin will take place. The fast-growing basal keratinocytes will pick up melanin from the surrounding melanocytes. The keratinocytes will get pushed up higher and higher as cells beneath them multiply. As they rise they will begin to produce large amounts of keratin, then they will lose their organelles as they die. As the dead cells rise, they will stay tightly bound together in a column, forming the hair shaft.

The basal cells go through growth cycles, the length of which depends on where they are found in the body. Eyelash hairs have a very short cycle of only a few months. Hairs on the scalp have a cycle of several years. The active part of the cycle is called the **anagen** phase. (“Ana” is Greek for “up.”) During anagen, the hairs do what we just described in the last paragraph. Scalp hairs spend several years in this stage. Then comes **catagen**, when the basal cells divide less frequently and the whole follicle shrinks. (“Cata” is Greek for “down.”) This stage lasts for a few weeks. Lastly, there is the **telogen** phase. (“Telos” is Greek for “far away.”) In this phase, the hair bulb actually detaches from its blood supply and goes “far away” from the dermal papilla. Telogen is the resting phase, where the follicle just sits and rests. Then, after a couple of months, stem cells from “the bulge” migrate down to the bottom and begin to grow a new bulb. The bulb reattaches to the papilla and a tiny hair begins to grow. This new hair pushes the dead hair above it up and out. We lose 50 to 100 hairs on our head each day due to new hairs pushing out old ones. (NOTE: Stem cells in the bulge also help to repair tears in the epidermis above them. They turn into keratinocytes to form temporary patches.)

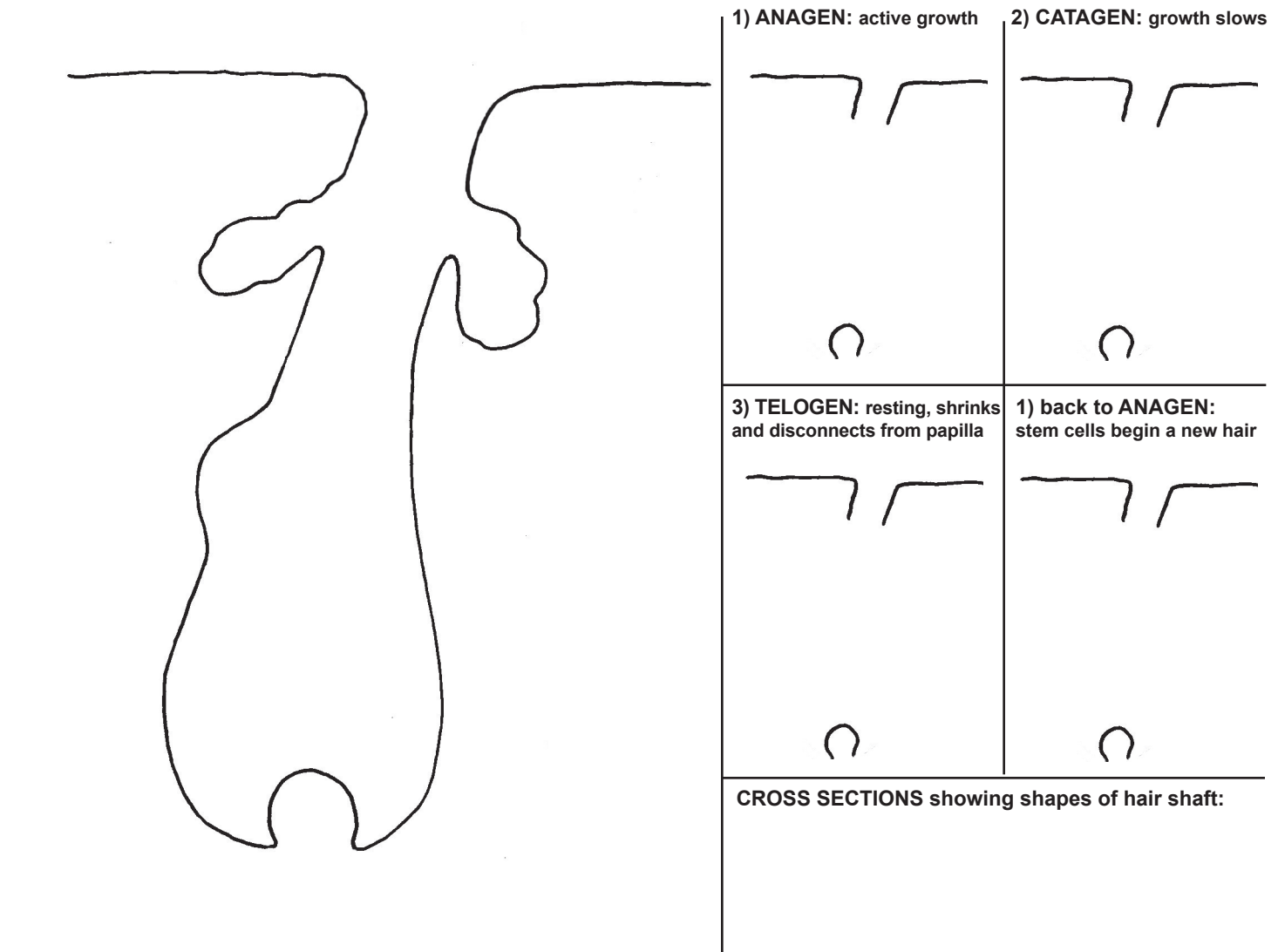
Humans have about 100,000 hair follicles on their scalp. Each follicle goes through this complete cycle about 20 times in our lifetime. The timing of the phases of the cycle are controlled by “growth factors” produced in other places in the body, often in glands. The growth factors are carried by the blood and come into the follicle through the dermal papilla. Significant changes in hair follicles occur during puberty, for example. Skin that was hairless in childhood suddenly begins to grow hair.

Nails grow in much the same way as hairs, except that they don’t take up melanin, and the end result is a flat “plate” not a thin shaft. Nails have a basal area with actively growing cells going through mitosis. Like the keratinocytes of the skin, nail keratinocytes produce large amounts of keratin, then gradually die. The dead cells full of keratin are pushed out further away from the basal area, causing nail growth. Nails on fingers grow at a rate of about 2 to 3 centimeters a year. Fingernails grow about four times faster than toenails. (Index fingernails also grow faster than pinky nails.) The actively growing base of the nail is sometimes called the **matrix** (one of the most over-used words in science, along with medulla, cortex, and cuticle). The basal matrix controls the shape of the end product, and in animals can make horns and claws.

The tissue under the nail is called the **nail bed** and is full of capillaries, giving nails their pink color. The white half-moon shape at the bottom of the nail is the **lunula**, (“Luna” means “moon.”) The lunula is part of the actively growing matrix of basal cells. The lunula is best seen on the thumb and might not be seen at all on the pinky. The edges of skin around the nail are called the **nail folds**.

Hair and nails are part of skin and grow in much the same way. However, unlike skin, the keratinocytes in hair and nails don't produce destructive enzymes that cut the bonds between the cells. The cells stay firmly connected.

HAIR GROWTH CYCLE



NAILS

TOP VIEW:

SIDE VIEW CROSS SECTION:

59: TEETH and TONGUE

An embryo begins to develop teeth at as early as 6 weeks. That's amazing considering that it doesn't even have fingers yet. Primary (baby) teeth begin to develop at 6 to 8 weeks and permanent (adult) teeth begin to develop at 20 weeks. Fingers develop from 7 to 9 weeks. A baby is born with no visible teeth, but has both sets fully or partially developed already, up in the gums.

Teeth begin as tiny "buds" of cells that have decided to differentiate into teeth. Embryonic growth factor chemicals told these cells to be different from the cells around them, and turn into teeth. The bud grows larger and changes shape, and, as the number of cells increases, the cells differentiate again and become the cells that make the inner and outer parts of the teeth. Cells that form body parts often have names that end in "-blast," and in the teeth we find **ameloblasts**, **odontoblasts**, and **cementoblasts**. All of these cells function in a similar way, but to varying degrees. They all secrete protein fibers, such as collagen, as well as chemicals that make mineral atoms stick to the protein fibers. We find this process in bone, too, and will study it more in the first lesson on bone. The protein fibers and the minerals blend together to make a biological substance that is a lot like the reinforced concrete used in the construction industry to make buildings. The steel bars in the concrete are like the protein fibers, and the concrete itself is like the deposited minerals. Like concrete, minerals by themselves tend to be brittle. The protein fibers (often a type of collagen) function like the steel bars, giving a rigid but resilient, and slightly flexible, framework. (Some people might classify this as a type of "biomimicry" where humans have imitated engineering examples found in nature.)

The **ameloblasts** are responsible for making the hard, white **enamel** that forms the surface of the tooth. Enamel is the hardest substance found in the body. Ions of calcium (Ca), phosphate (PO_4) and the hydroxyl group (OH) combine to form a mineral substance called **hydroxy-apatite** (hi-drox-ee-ap-ah-tite), $\text{Ca}_{10}(\text{PO}_4)_6(\text{OH})_2$. The **odontoblasts** are responsible for making the **dentin**, a hard substance that lies right underneath the enamel. Enamel is mostly minerals with just a little protein fiber. Dentin has more protein fibers and a little less mineral content, so it is not quite as hard but much more resistant to impacts, whether the daily small impacts of chewing or the sudden traumatic impacts of injury. The ameloblasts and odontoblasts start out sitting in a line next to each other. Their products, enamel and dentin, pile up between them, and the cells get farther and farther away. By the time the enamel and dentin are fully formed, the ameloblasts are on the top of the tooth and the odontoblasts are deep in the tooth, on the inside of the dentin. The ameloblast die and disappear after they are done forming the enamel. After your tooth development period is over, you can't replace that enamel because the cells are no longer there. The odontoblasts survive, and will be part of the living tooth.

The **cementoblasts** produce **cementum**, a substance that is about 50% protein fibers and 50% minerals. Cementum is the layer that fastens the tooth to the gums. Unlike enamel and dentin, cementum is constantly produced throughout our life. Surprisingly, it has the highest fluoride level anywhere in the tooth. Fluoride treatments by dentists add fluoride to the outer mineral layer of the enamel.

The inner part of the tooth is called the **pulp**. It contains many blood capillaries, some lymph capillaries, and nerve endings that can sense hot, cold and pain. The pulp narrows and goes down through the roots, in channels called **root canals**.

The teeth are surrounded by the gums, more properly called the **gingiva**. The gingiva tissue is basically the same as the epithelial tissue found in skin. There are basal cells that produce keratinocytes, which gradually produce more keratin and eventually die and become very flat (squamous). Gingiva can be hard and stick to the bone tightly (lower gums), or it can be unattached and free to move around (the little bits of gum between your teeth). We can keep our gums healthy by using dental floss to keep food particles and bacteria from collecting in the space between the tooth and the gingiva. Healthy gums will not bleed at all when flossed. Inflammation of the gingiva is called **gingivitis**. ("-Itis" means "inflammation.")

There are 20 primary (baby) teeth. The permanent teeth number 32, though 4 of those are the "wisdom" teeth than most people have removed during their teen or early adult years. The four types of teeth are **incisors** (central and lateral), **cuspids** (canines), **bicuspid**s (first and second premolars), and **molars** (three sets). It is easy to see from their shape and where they are located in the mouth what role they play in biting and chewing.

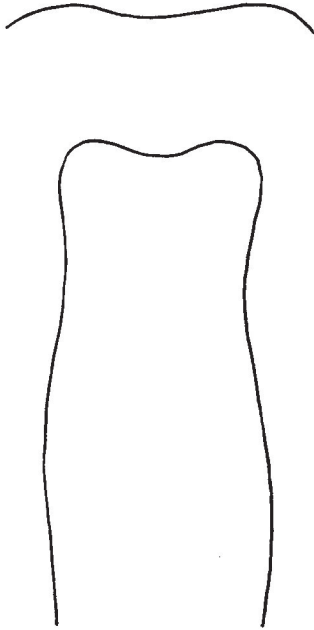
The tongue is a muscular organ. It is made of muscles and is attached to muscles. It is covered by a type of epithelium called **mucosa** or **mucosal membrane**. We find mucosal tissue lining all body cavities such as mouth, nose, stomach, intestines, lungs and reproductive organs. Mucosa can tolerate being wet all the time, unlike our regular skin. Our entire mouth, except for our teeth, is covered with mucosal tissue. Somehow or other, when the mucosal tissue gets to the edge of our lips, it knows to stop. The mechanism that allows cells to know their exact location has yet to be discovered. On the tongue, the mucosa covers thousands of little bumps called papillae.

Underneath the tongue we find the **frenulum**, which attaches the tongue to the floor of the mouth. We also see bluish veins (though blood is never blue!) and two barely visible pores (at the base of the frenulum) that are openings to salivary ducts. These ducts are like very long pipes that run all the way to the salivary glands that are under the tongue and at the top of the neck.

There are four types of papillae: **circumvallate** (or just vallate), **foliate**, **filiform** and **fungiform**. The diagram shows where each type is found. They all contain taste buds except for the filiform. The filiform papillae only provide friction (for chewing) and sensation (touch, hot, cold, pain). The other three types have microscopic taste buds that can sense sweet, sour, salty, bitter and umami (savory). (NOTE: Those old "maps" of the tongue are outdated. It is now being taught that all parts of the tongue are equal.) The fungiform papillae get their name from the fact that they are shaped like mushrooms.

Taste buds are made of a bunch of **receptor cells**, some of which have cilia protruding out the top. Other cells make a basal layer. Dendrites of neurons go up between these cells, waiting for the cells to stimulate them to begin an action potential. The receptor cells will be triggered by the chemicals present in food particles. The action potential will continue through a series of neurons until it reaches the part of the brain that interprets tastes. The brain will turn the electrical signal into a taste sensation.

Most of a tooth lies below the surface. Teeth have deep roots that go down into the bone. The white enamel is the hardest substance in the body and is non-living. The inner pulp is alive.



Enamel was made by ameloblasts, which disappear once they have done their job.

Odontoblasts made the dentin and are still there on the inside of the dentin, next to the pulp.

periodontal membrane

Cementum is secreted by cementoblasts. It is 50% collagen, and 50% minerals such as calcium, phosphorus, and fluorine. Unlike enamel and dentin, cementum is made throughout our lifetime.

The tongue is much larger than it appears. We see the body of the tongue, but the large "root" is below the surface. The tongue is made of many muscles, and it connects to many others.

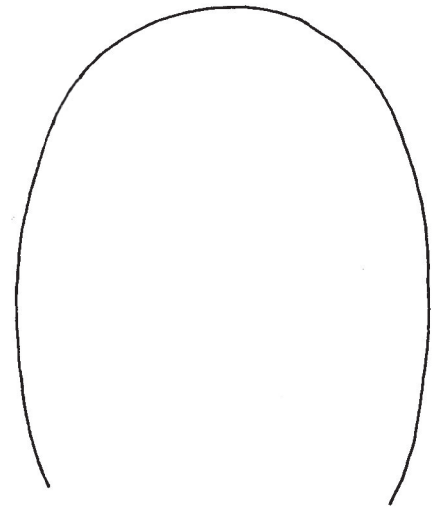
Four types of lingual papillae:

1) circumvallate
We only have 8-12 of these.

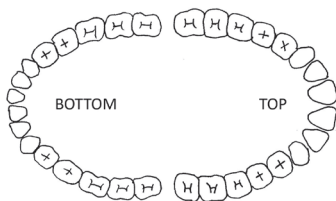
2) foliate
Located along the back sides.

3) filiform
These are most numerous and we have thousands.

4) fungiform
We have 200-300 located mainly near tip and sides.




Those tongue maps are no longer valid. Current research shows that all areas of the tongue can taste sweet, sour, salty, bitter and umami (savory).



Types of teeth:

Incisors
Cuspids ("canines")
Bicuspids
Molars

Underneath the tongue

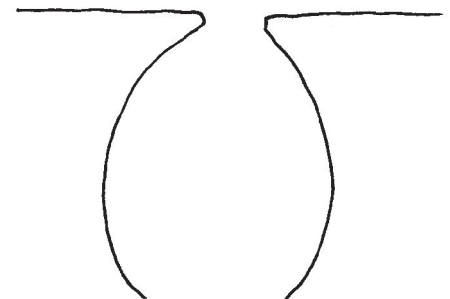


PAPILLAE



TASTEBUDS

Taste receptors in taste buds are similar to smell receptors in the nose. Both are triggered by chemicals. The cells start an action potential in the nearby neurons, which travels to the brain where it is interpreted as an odor.



The bumps you see on your tongue are papillae, not taste buds. Taste buds are microscopic. The filiform papillae do not have taste buds. They simply provide friction and sensation. (Animal tongues (notably cats) often have very large and long papillae, making their tongues feel rough.)

Taste buds can only sense sweet, sour, bitter, salty and umami (savory). Most of taste involves smell.

60: MOUTH, NOSE and THROAT

In this drawing we are seeing a cross section of the head as if it was sliced right down the middle. We won't see the ear or the jaw bone or any of the neck muscles. We've even removed the dividing wall in the nose, called the **septum**. The septum is that thing that divides your right and left nostrils. In this view we are seeing the interior of the right nostril and the right side of the sinus area. We'll see a little bit of the brain in this drawing, plus the top of the spinal cord.

In this view of the tongue we can see a few of the muscles, but there are others that have been removed because they attach to the head in places near the ear and jaw which have been removed. The tongue is made of 8 muscles all together; 4 of them are **intrinsic**, or completely within the tongue, and 4 are **extrinsic** and attach to places outside of the tongue. To talk or eat you must coordinate the actions of all 8 muscles. These muscles have difficult names that you only need to know if you are studying to be a doctor or a speech therapist.

The surface of the tongue is covered with epithelial tissue. The top of the tongue is called the **dorsum**. The word root "dors" always refers to the back of something. We just need to imagine that the tongue is like a 4-legged animal where its back is actually the top. Under the epithelium is a layer of muscles running parallel to the dorsum. Then under that are some muscles that run perpendicular, going downwards. On the bottom you can see one of the extrinsic muscles that attaches to bone. It is attached to the jaw bone at one end and a tiny bone called the **hyoid bone** at the other end. The hyoid is a bone that most people are not aware of. It's a small U-shaped bone that is held in place by muscles stretching out from it in every direction. If the muscles disappeared the hyoid bone would fall out. In this drawing we only see a cross section of the hyoid bone so we can't see its U-shape. However, we do see it attaching to a part called the **epiglottis**. The epiglottis is a piece of soft cartilage covered with epithelium. It is a flap that covers the **trachea** (air pipe) during swallowing so food does not get into your lungs. Nerves running into the epiglottis provide us with our gag reflex.

Right under the epiglottis is the top of the trachea. Behind it is the **esophagus**, which is the food pipe that goes into the stomach. Also at the top of the trachea is the **larynx**, which is the area of the **vocal chords**. The opening between the vocal chords is called the **glottis**. The vocal chords are two pieces of soft cartilage that can be stretched or relaxed to make them short and tight, producing high-pitched sounds, or long and loose, producing low-pitched sounds. (The air you breathe always goes past the vocal chords, but if you don't have them stretched tight, no sound is produced.) The larynx area is protected by the **thyroid cartilage**. (When the thyroid cartilage sticks out noticeably, it is often called the "Adam's apple.") The larynx area has many muscles attached to it at various points, which help with speech and swallowing.

The area right behind the tongue is called the **pharynx**. The palatine tonsils are in this area, but we can't see them in this picture because it is a cross section. Notice the lingual tonsil that we learned about in the last drawing. At the very top of the pharynx, almost in the sinuses, we find the **adenoids**. The adenoids are lymph tissue, just like the tonsils. In this area we also find tiny holes which are the openings of the **Eustachian tubes**. We will learn about the Eustachian tubes in the lesson on the ear.

The top of the mouth area is called the **hard palate**. (*PALL-it*) The back of the palate is the **soft palate**. You can use your tongue to feel the difference between the hard and soft palate. Both hard and soft palates have lots of collagen, but only in the hard palate do we find the collagen filled with minerals. The soft palate stays soft because it does not fill with minerals. The very tip of the soft palate is called the **uvula**. The uvula gets pressed against opening the sinuses when you swallow. This area around the uvula is sometimes called the **nasopharyngeal** area, using a combination of the words nose and pharynx. (Don't let long words scare you—just look for smaller words inside them.)

The nostrils lead into **nasal passages**. The nostrils are lined with hairs that will hopefully prevent the entry of dust and dirt. Inside the nasal passages are three long folds called **conchae** (singular: **concha**). They have a framework of bone covered in mucosal epithelial tissue. The folds are also sometimes called the **turbinates** because their job seems to be to create turbulence in the stream of air that is passing through. The turbulence slows down the air and makes it come into contact with the mucosal tissue for a longer period of time. Coming into contact with the mucosa warms the air and adds moisture to it, making it more comfortable for our lungs to breathe. Cold, dry air is irritating to the lungs.

The nasal passages have little side passages called **sinuses**. There are four distinct sinus areas. The two that we are familiar with are the largest ones, the **maxillary sinuses** behind our cheek bones and the **frontal sinuses** behind our forehead. When we have a sinus infection it is usually in either the maxillary or the frontal sinuses. The sinuses get infected more easily than the central nasal passages because the sinuses are less open. During a cold or flu, inflammation in the sinuses can cause them to stop draining. The tear ducts also drain into the nasal passages, which is why our nose runs when we laugh hard or cry.

The other two sinus areas are less well known. Right above the adenoids we find the **sphenoid sinus**. It also has small ducts that allow it to drain into the maxillary sinus. The sphenoid sinus provides a little bit of protection for the brain part behind it, the **pituitary gland**. The pituitary gland is a marble-sized brain part that controls the production of many hormones. (We'll learn more about it when we get to the endocrine system.) The sphenoid sinus is in the middle of the sphenoid bone. This bone is part of the bottom of the skull, but when separated from the rest of the skull bones, it looks a bit like a butterfly. You can't see any of the butterfly shape in this drawing because it is a cross section. We'll see the sphenoid bone again in a later lesson.

The **ethmoid sinuses** are located in the **ethmoid bone**. The ethmoid might just be the most complicated-looking bone in the body. It is so complicated that each side of it is called a **labyrinth**. ("Labyrinth" comes from Greek mythology—a story about an impossibly complicated maze that a hero must go through.) A few of the labyrinth bones project into the nasal passages. These are the bones inside conchae, and form the rigid framework for the structures called **conchae**. (*kon-kee* or *kon-kay*) The ethmoid sinuses and most of the ethmoid bone cannot be seen in this drawing because it is a cross section and we've removed the entire left side of the head.

Very related to the tongue and teeth are the **salivary glands**, though we can't see them in the main drawing. Salivary glands provide the necessary fluids for the taste buds to function, and for us to swallow comfortably. Saliva contains an enzyme called **amylase**, which begins to break down starches found in bread, rice and pasta. Saliva helps teeth by neutralizing acids. Bacteria are helped by a slightly acidic environment so the presence of acid promotes tooth decay. (Sugary carbonated beverages have both sugar and acid, which is why they are so bad for your teeth.) There are three main areas of salivary glands. The **parotid glands** are located on the upper jaw. These are the glands near your ear that will twinge when you blow up a balloon or taste something super sour. The **sublingual glands** are located right where their name says: under the tongue. The **submandibular glands** are under the mandible (jaw). The submandibular and sublingual glands both have ducts that come out under the front of the tongue, as we saw the last lesson.

The "roof" of the nasal cavity is the part of our nose that can smell. There is a special patch of epithelial skin, about the size of a very large postal stamp, that contains millions of **olfactory receptor cells**. (The word **olfactory** is the technical term used to describe a body part involved in the sense of smell.) These receptor cells are actually a type of neuron. These neurons are unlike any other neurons in the body because they are constantly being replaced. As a general rule, you are born with all the neurons you'll ever have. The neurons in your brain and muscles stay with you for your entire life. If they are damaged they have a limited ability to repair themselves, but they don't regrow like skin cells do. This is why injuries to the spinal cord can be permanent. However, here in the nose, these receptor neurons are being replaced every few months. The new neurons come from stem cells that live at the bottom of this epithelial tissue.

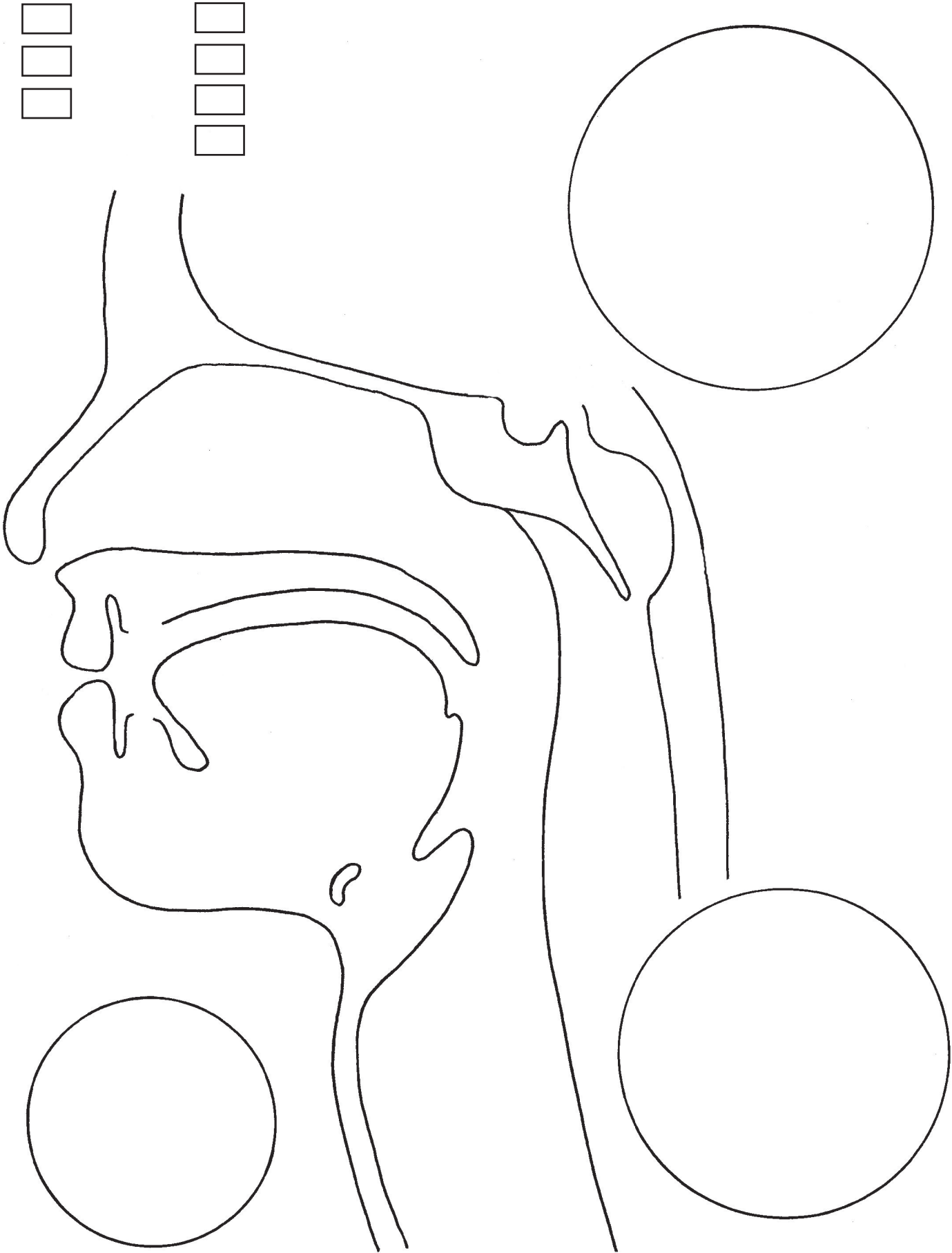
The receptor neurons have cilia that reach out into the nasal cavity. Other cells in the epithelium, called **Bowman's cells**, produce a watery mucus and specialized proteins that help molecules stick to the receptors. When odor molecules are inhaled through the nose, some of them will stick to this mucus and thus come into contact with a receptor neuron. If the shape of the odor molecule happens to be close enough to the shape of a receptor, it will bind to it. That will trigger the neuron and make it begin an action potential (electrical signal). The axons of the receptor neurons are bundled together, and these bundles go up through small holes in the ethmoid bone and then into a brain part called the **olfactory bulb**. The olfactory bulb gathers all the signals coming from the olfactory epithelium and sends them on to other brain parts. Here we find another difference between smell and our other senses. The input signals from our other senses go to a relay center in the middle of the brain where the brain decides what to do with them. The relay center then sends the signals on to other brain parts. However, the signals coming in from the nose don't go to this relay center, but go directly to other brain parts. One of these brain parts interprets the signals as what we could call a "smell." Two other brain parts that get the signal are the memory and the emotional center. They say you never forget a smell, and perhaps this is why. The strong link between smell and memory is a survival mechanism that helps wild animals avoid danger. Also, smells can trigger emotions and reflexes. Delicious smells can make our mouth water. Smells that we first encountered during a negative situation can trigger those same negative emotions even when the situation no longer exists.

Smells are combinations of odor molecules. When you smell pizza, you are sensing a complex combination of molecules coming from tomatoes, spices, cheese and bread. Yes, some of the pizza molecules actually become airborne and float around. (Heat makes molecules move around faster, causing more surface molecules to launch into the air, so a hot pizza will produce more smell than a cold one.) The odor molecules trigger only the neurons that match those molecules. So each smell triggers a unique pattern of receptors. Our brain categorizes those odors, though, so that we can find similarities between smells. A smell can be "fruity," for example, without being identified as specific fruit.

Most of our sense of taste actually comes from our sense of smell. As we chew our food, molecules from the food go back through the pharynx and then up into the nasal cavity. Undoubtedly, you've discovered that if you hold your nose, your sense of taste is much diminished.

We can see a few brain parts in this drawing. We've already mentioned the **olfactory bulb** and how it relays signals from the olfactory neurons to several other brain parts. Above the olfactory bulb we see the main part of the brain, the **cerebrum**. We've also mentioned the **pituitary gland** and how it sits in the little "pit" sculpted out for it in the sphenoid bone. Just behind the adenoids we find the **pons**. The word "pons" comes from the Latin for "bridge." The pons is like a bridge between the upper brain (the part we recognize as "brain") and the lower brain, or brain stem, that controls basic functions like breathing and the pumping of the heart. The pons is primarily involved with sleep and helps to control your waking and sleeping cycles. Research has suggested that our REM sleep—the periods when we dream—originate from the pons.

Behind and underneath the pons we find the **medulla oblongata**, or "brain stem." This is the area that controls breathing and heart rhythm. The medulla oblongata then turns into the spinal cord and goes down through all the vertebrae (back bones). Further behind the pons we see part of the **cerebellum**. "Cerebellum" means "little brain." The cerebellum has a texture very different from the rest of the brain. It sits below the main part of the brain, at the top of your neck. The cerebellum helps with balance and coordination and muscle memory. The cerebellum seems to be where memories like "how to ride a bike" or are stored.



61: THE EAR

The ear can be divided into three main areas: the outer ear, the middle ear, and the inner ear. The outer ear is what we think of as the "ear." Technically, the outer ear also includes the ear canal, or auditory canal, most of which we cannot see. The technical word for just that outer flap of skin we call our ear is the **pinna**. The pinna is a complicated looking shape and we might wonder if there is anything significant about this shape. Scientists think that the shape of the pinna might help to collect and direct sound waves into the ear canal, especially the sound of the human voice. There are names for the various parts of the pinna. The only names we'll learn here are the **lobe** (which you already know), the **helix** (curly outside rim), the **antihelix** (curly inner shape), and the **tragus** (that flap you push on when you want to close your ears and not hear something).

The outer ear ends at the **eardrum**, also called the **tympanic membrane**. The eardrum is a thin, round membrane stretched across the end of the canal. It is not completely flat, but is slightly cone-shaped, bending in to the middle ear. The eardrum vibrates when sound waves hit it. The sound waves are passed along to the parts of the middle ear.

Sound is made of mechanical pressure waves that travel through the air. Very high sounds are made of waves that are short and travel quickly. The highest sound a human ear can hear has a wave speed, or frequency, of about 16,000 waves per second. (Some charts list 20,000 as the upper limit.) Low sounds are made of waves that are long and travel more slowly. The lowest sounds our ears can hear have a frequency of about 20 waves per second. The unit of measurement for sound is **hertz, Hz**. Hertz means waves, or "cycles," per second. So we can say that humans can hear a range of sound from 20 Hz to 20,000 Hz. Many animals can hear much higher frequencies. Cats can hear sounds that mice make at about 75,000 Hz. Brown bats can only hear high sounds from 10,000 to 90,000 Hz. Don't bother talking to a bat because your voice is so low (100-200 Hz) that it can't hear you!

The middle ear, on the other side of the eardrum, begins with the **malleus** bone, also called the "hammer." ("Malleus" is Latin for "hammer.") The ends of this bone touch the eardrum and pick up vibrations. The vibrations move the malleus back and forth. The malleus is connected to the **incus**, or "anvil." ("Incus" is Latin for "anvil." The anvil is a tool used by a blacksmith. It is heavy block that the hammer strikes.) Connective tissue ligaments hold these bones in place. At the end of the incus we find the tiny **stapes** (*stay-peas*). The stapes is often called the "stirrup" because it does indeed look like a stirrup on a horse saddle--the part where your foot rests. ("Stapes" is Latin for "stirrup.") These three bones of the middle ear are the smallest bones in the body. They transfer the vibrations from the eardrum to the inner ear where they will be turned into electrical signals.

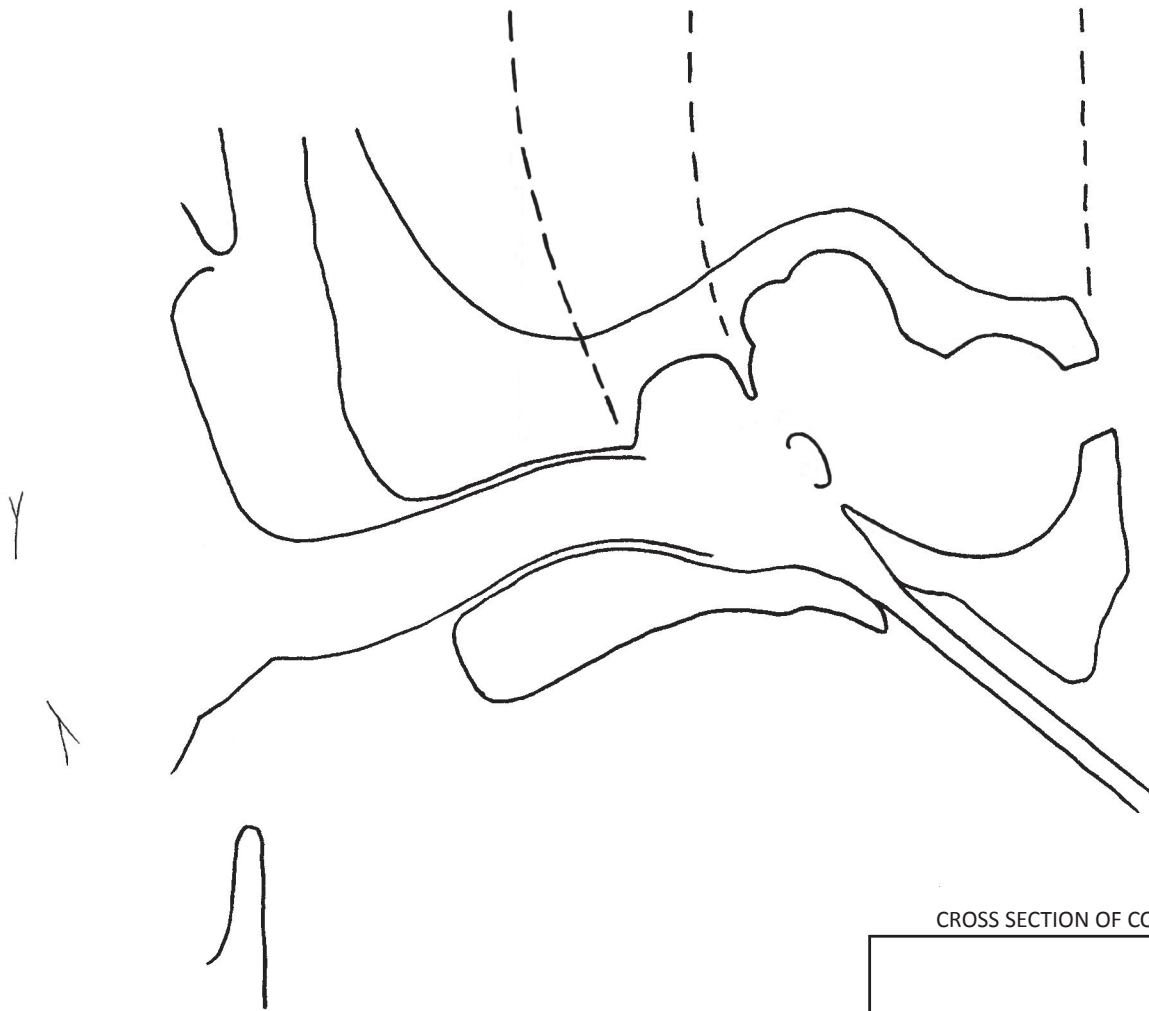
The space around these bones is not filled with fluid, but is an air space. Problems might arise if the air pressure inside this space is higher or lower than the air pressure outside of the head, so there is a thin tube that connects the middle ear to the outside world. This tube is called the **Eustachian tube**, named after the scientist who discovered it in the 1500s, Bartolomeo Eustachi. The Eustachian tube is only a few millimeters in diameter and is flattened shut most of the time. When you go up in an airplane, the air pressure around you drops, and the high pressure air in the middle ear must escape through the Eustachian tube. We often experience this sudden opening of the tube as a "popping" sensation inside our ears. Divers experience the opposite, with the pressure around them suddenly increasing. They must make a yawning motion in their nasopharynx region in order to open the Eustachian tube and let the pressure equalize.

The end of the stirrup (stapes) is where the inner ear begins. The stirrup touches an oval area called the **oval window**. The oval window is part of a structure that has two parts, the **cochlea** and the **vestibular system**, but looks like it is just one part.

The **cochlea** gets its name from the Greek word for snail shell, "kokhlias." The cochlea sits inside a "pocket" of bone in much the same way that the pituitary gland does. The cochlea is a set of coiled tubes that are filled with fluid. This fluid absorbs the vibrations that come in through the oval window. If you straightened out the cochlea and cut a cross section, it would look like two tubes stuck together. Vibrations enter through the top tube and leave through the bottom one. The end of the bottom tube touches the outside of the cochlea at a place called the **round window**. The oval window and round window work together, pulsing in and out as vibrations travel through the fluid. When the oval window presses inward, the round window pops out, and vice versa.

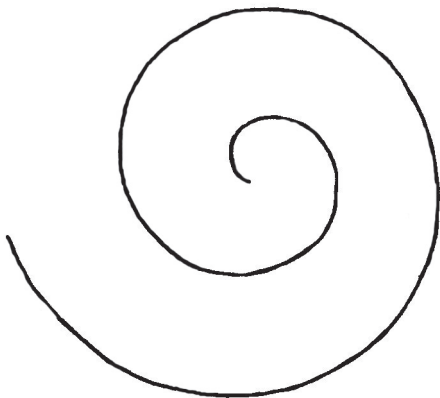
Between the tubes we find the **organ of Corti**. This long and thin little "organ" has cells that vibrate to certain frequencies. These cells are located on the **tectorial membrane**. When the organ of Corti is flexed up and down by the sound vibrations the tectorial membrane rubs "hairs" at the ends of **hair cells**. This causes the hair cells to depolarize and release neurotransmitters that will start an action potential in the dendrites of nearby neurons. (The inner hair cells are the ones that send signals to the brain.) The neurons get bundled as they exit the cochlea and become the **cochlear nerve** that goes into the brain. In the brain these electrical signals will be interpreted as sounds. High sounds are picked up by the first part of the cochlea, closer to the oval window. Low sounds are picked up near the center of the spiral.

The other part of the inner ear is the **vestibular system**. (In Latin, a "vestibule" is an entrance hall.) This is what gives us our sense of balance. The main body of the system is the **vestibule**. There are also three C-shaped tubes called **semi-circular canals**. The canals contain fluid that sloshes back and forth as we move our head. Each canal senses a different motion of the head: 1) up and down in a "yes" motion, 2) back and forth in a "no" motion, and 3) when the head tips down toward a shoulder. All together, the semi-circular canals are sometimes called the **labyrinth**. We saw this word in the lesson on the sinus. (The word labyrinth is a very general word and can be applied to any part that has a complicated, maze-like structure.) Sensor cells on the inside of the semi-circular canals are connected to neurons that send signals to the brain. As the fluid moves around the brain gets information on which way the head is tipped.



SENSITIVITY AREAS OF THE COCHLEA:

16 Hz = lowest note on tuba
 65 Hz = lowest note on cello
 261 Hz = "middle C"
 440 Hz = "A" for tuning orchestra
 4186 Hz = highest note on piano
 1,000-8,000 Hz - bird songs



SOUND WAVES:

Long waves sound low.

Short waves sound high.

CROSS SECTION OF COCHLEA:



ORGAN OF CORTI:



62: THE EYE (anatomy)

The eye is so complicated we need to take two lessons to cover it. This lesson is about anatomy: drawing and naming all the parts. The next lesson will be about physiology, which is how the parts work.

The eye is a round sphere about an inch (3 cm) in diameter. We only see the front part of the sphere, peeking out from between our eyelids. The outside covering of the eye is made of white connective tissue (collagen type 1, plus elastin) and is called the **sclera**. ("Scler" means "tough or hard.") The colored part of the eye is called the **iris**. ("Iris" is Greek for "rainbow.") Humans have an iris that is fairly small, so that the white sclera is seen all around it. If you've ever looked at a dog's eye, the colored area is so large that you have peel back the skin around the eye to see any white. The fact that our eyes have a visible iris makes it much easier for us to tell from a distance in what direction someone is looking. The iris is like a donut with a hole in the middle. The hole is called the **pupil**. The pupil's job is to let light into the eye. If there is very little light, the pupil opens and becomes very large so that as much light as possible comes in. If there is too much light, the pupil shrinks and becomes very small. The size of the pupil is controlled by a ring of muscles inside the iris.

The color of the iris is caused by the amount of **melanin** produced by melanocytes. Human eyes contain various amounts of melanin, which is always brown or black. A small amount of melanin will produce light brown eyes and a lot of melanin will produce eyes that are almost black. Blue eyes are caused not by a pigment, but by the scattering of light—the same phenomenon that makes the sky blue. Green and hazel eyes are caused by a combination of the light scattering effect and a very small amount of melanin. If the melanocytes are non-functional or are completely missing, this causes a condition called **albinism**. Albino eyes look pink. People with albinism usually have little or no pigment in their hair and skin, as well.

The iris and pupil are protected by the **cornea**, a clear layer that is connected to the sclera. The cornea is made of connective tissue that is similar to the sclera. The main difference is that the cornea tissue is dryer, causing it to be transparent. Between the cornea and the iris there is fluid called **aqueous humor**. (Remember, "humor" means "fluid.") There is also a very small chamber between the iris and the lens, which is also filled with this fluid. The fluid is produced by the **ciliary body**, which is behind the lens. There are tiny drain holes to drain off old fluid as new fluid comes in to replenish the old. These drain holes are called **Schlemm's canals**. These canals are very similar to lymph vessels, taking away extra fluid and recycling it. If these drain holes become clogged, too much fluid will build up behind the cornea, causing a condition called **glaucoma**. Glaucoma can be very damaging and can even cause blindness.

Behind the pupil is the **lens**. The lens has a central core and a tough outer capsule. If the core becomes cloudy it can cause a condition called **cataracts**. An eye surgeon must drill into the lens and replace the defective tissue. The lens is connected to the ciliary body by thin ligaments called **zonules**. The ciliary body is flat and circular and goes all the way around the lens. It contains a ring-shaped muscle that can change the shape of the lens when it tightens or relaxes. When it is relaxed, the lens is more flat and will focus on things that are far away. When the muscle tightens, the lens gets more round and will focus on things that are close to the eye. The ciliary body is also responsible for making the aqueous fluid that fills the chambers in front of the lens.

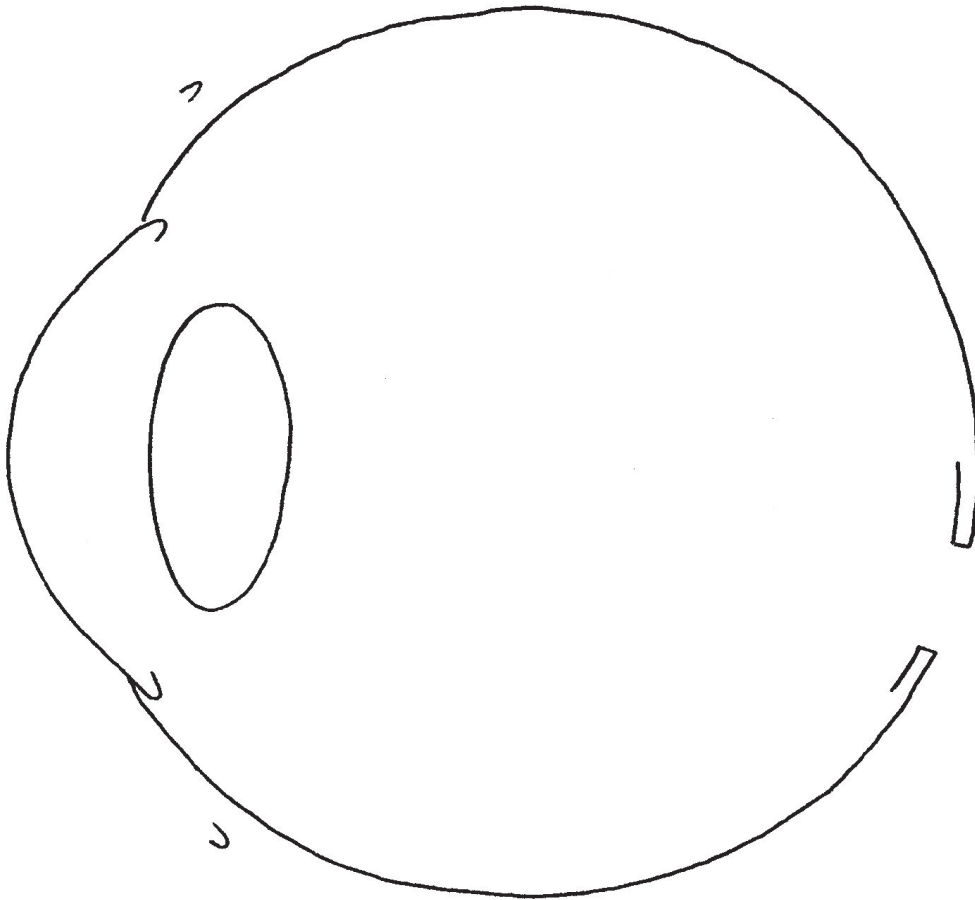
The space behind the lens is filled with a "gel" called **vitreous humor**, or the **vitreous body**. "Vitreous" means "glass-like." This gel fills the interior space and keeps all the parts in place. There is a small canal, the **hyaloid canal**, that runs down the middle, from the lens to the back of the eye. When the lens thickens to focus on something close to the eye, its volume increases just a bit. This increased volume could cause problems as it presses on the vitreous body. The fluid in the canal is able to absorb this pressure, so no harm is done. This is a trim detail of design that most people don't know about.

Another lesser-known detail of the eye is the presence of oil glands in the eyelid. Inside the eyelid is a flat piece of connective tissue called the **tarsal plate**. ("Tarsos" is Greek for "flat surface.") This plate makes the eyelid just stiff enough to keep its shape, while still allowing it to be soft and flexible. Inside this plate are microscopic oil glands that make a special kind of oil for lubricating the eye. The oil keeps the water on the surface of the eyeball from evaporating too quickly. It also makes the edge of the eyelid just oily enough to form a slight barrier that keeps normal amounts of water from running down your cheeks. Of course, when you cry, the system is overloaded and tears do roll down your cheek. However, small daily amounts of water are held back. The inside of the eyelid and the visible part of the sclera are covered with a protective layer called the **conjunctiva**. Infections of the conjunctiva are very common and are often called "pink eye."

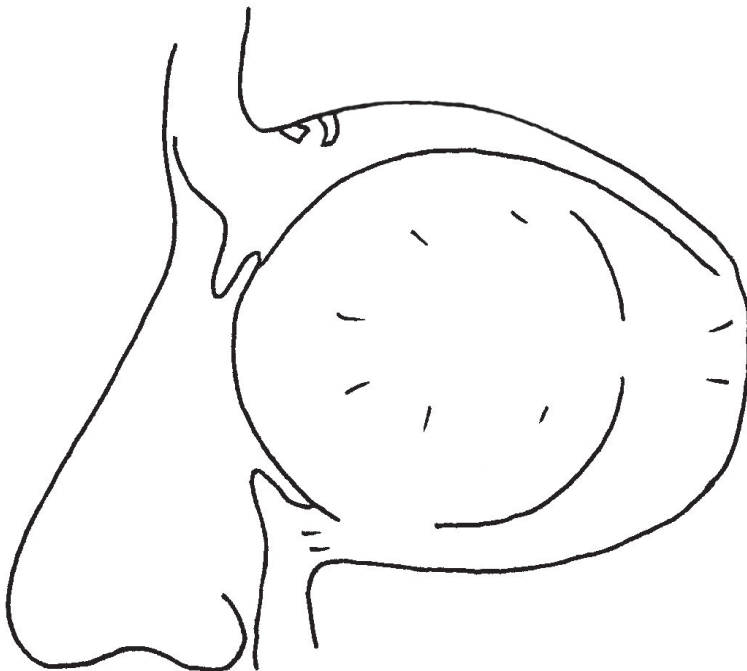
The movements of the eyeball are controlled by six muscles. Four of them are called **rectus** muscles. "Rectus" means "straight" so the rectus muscles move the eye either straight up and down or side to side. The rectus muscles are **superior** (meaning "on top"), **inferior** (meaning "on the bottom"), **lateral** (meaning "on the side"), and **medial** (meaning "towards the middle"). There are two **oblique** muscles that rotate the eye clockwise or counterclockwise, allowing for diagonal motion. The superior (top) oblique muscle goes through a little loop called the **trochlea**. The trochlea acts like a pulley, letting the muscle be attached behind the eye instead of to the side. Five of these muscles attach to an area of connective tissue at the back of the **orbit** (the space where they eyeball sits). Only the inferior oblique does not. Also, the muscles that pull the eyelid up and down attach to the back of the orbit. Only the front part of these muscles is shown in the diagram.

The **lacrimal gland** is located above the eye, on the side away from the nose. The lacrimal gland makes tears that keep the eye moist and clean. ("Lacrima" is Latin for "tears.") The little indented place at the "corner" of the eye is called the **lacrimal caruncle**, or just the **caruncle**. The caruncle contains some sweat glands and sebaceous glands covered with a layer of protective tissue. Near the caruncle on both upper and lower lids are tiny holes called the **puncta**. (One punctum, two puncta.) The puncta lead to the **lacrimal ducts** that go down into the nose. These ducts are drains for the tears after they have washed the eyeball.

REAR VIEW of ciliary body:



EYE MUSCLES (left eye shown)



63: THE EYE (physiology)

The eye must constantly adjust its focus from near to far, far to near. All day long we are looking back and forth from distant objects to things that are very close. The light from these objects must be focused onto the **macula** of the retina, and onto the **fovea**, in particular. The fovea is the "sweet spot" of the retina because it contains millions more cones than any other place on the retina. In order to make sure that the light entering the eye hits the fovea, the lens can change shape. When an object is far away, the lens must be more flat. When an object is very close, the lens must become more round. The physics of lenses is the same, whether the lens is made of glass, plastic, or living tissue. Flatter lenses focus on distant object and rounder ones focus on closer objects. However, with glass and plastic the shape of the lens cannot change, of course.. Only living lenses can change their shape to adjust for all circumstances. The process of adjusting is called **accommodation**.

We learned that the ciliary body is in charge of changing the shape of the lens. Inside the ciliary body is a ring of muscle. When this muscle relaxes, it gets larger. This stretches the zonules (those "zonules of Zinn"), pulling the lens into a flatter shape. When the muscles contract, the lens appears to get pushed into a more round shape. Exactly how this happens is still being debated. There are two leading theories. One theory says that the zonules all relax, and the other theory is that only some of them relax. It's important to remember that scientists don't have everything figured out. There is still a lot we don't know.

The ring of muscles in the iris is also contracting and relaxing all the time. There is a feedback mechanism in the eye that automatically controls the size of the iris. If there is too much light, the muscles contract and shrink the pupil. If there is not enough light, the iris will open wider.

The image that hits the macula is upside down. That's just the way light works. The optic nerve will take this information to the brain, and the brain will flip the image and make us think we are seeing it right side up. The vision center in the brain is not right behind the eyes as you might expect, but at the very back. Also, the sides are reversed with the right side of the brain controlling the left eye and the left side of the brain controlling the right eye.

If you look into an eyeball with an ophthalmoscope, you will see two distinct spots. One will be the macula. The other is the **optic disc**, the place where the optic nerve leaves the eye. The optic nerve also contains many blood vessels, so you will see vessels coming out of the optic nerve area. The nerve is to the outside of the eye from this viewpoint.

The receptor cells in the retina are of basically two kinds: **rods** and **cones**. (We must say "basically" because a third kind was discovered in the 1990s and is believed to be the cell that controls the pupillary reflex. However, almost every source you will read in a book or on the web will say there are two kinds.) The rods are very long and thin, and the cones have a cone shape on their ends. They have a similar structure, with a nucleus located in a central area, and the skinny rod or cone shape on one end and a "synaptic" ending on the other. The synaptic endings look a bit like an axon terminal and they do a similar job, but technically these are not nerve cells in the same way that neurons are.

The rod or cone shaped ends of these cells contain about a thousand discs made of phospholipid membrane. The membrane is there to hold a very important molecule in place: **rhodopsin**. ("Rhodopsin" comes from the Greek word "rhodon" meaning "pink," and the Greek word "opsis" meaning "sight.") This is the molecule that responds to light. The rhodopsin molecule contains a smaller molecule called **retinal**, which the cells make from vitamin A. The retinal molecule changes shape when light hits it. This change of shape starts a short cascade of events that leads to the cell's sodium gates being opened up. Strangely enough, the cell is already full of sodium ions (Na^+). The addition of even more sodium ions causes it to become **hyperpolarized**. As we learned in lesson 52, **polarized** means more negative on one side and more positive on the other. This makes a cell ready for an action potential. The action potential happens when the ions rush back to the other side, **depolarizing** the cell. Then the cell has to reset again. In this case, light causes even more polarization. This **STOPS** the cell from sending a signal. So light stops these cells from sending signals! This seems backwards and certainly must have surprised the scientists who discovered it.


We have a strange system here. When they are NOT being stimulated by light, rod and cone cells are constantly releasing neurotransmitters (**glutamate**, from lesson 9) at their synaptic end. These transmitters, however, are **inhibitory**. (Excitatory transmitters cause (excite) cells to start action potentials, and inhibitory transmitters prevent (inhibit) them from doing so.) When light hits rod and cone cells, they stop releasing their inhibitory transmitters. The cells that they are connected to, the **bipolar neurons**, are then released from inhibition and can send a signal to the next cells in the line, the **ganglion cells**. The ganglion cells are the ones that have axons extending into the surface layer of the retina and then on into the optic nerve. Ganglion cells are the only ones that start a true action potential. The rods, cones, and bipolar cells use what is called a **gradient potential**, more like a dimmer switch than an off/on switch.

There are other nerve cells in and around the bipolar and ganglion cells. **Amacrine** and **horizontal** cells form horizontal connections between cells. (Amacrine comes from "a-" meaning "not," and "macro" meaning "big.") Amacrine cells connect rods and cones in such a way that they can function cooperatively. Horizontal cells connect ganglion cells.


Rods are very sensitive to light and a single rod can detect a single photon of light. Because of their sensitivity, rods can function when there is very little light. They give us our night vision. Rods are found all over the retina, but mainly outside of the macula. Because rods are found very far from the central focal point, they also give us our **peripheral vision**, at the edges of our field of sight. Cones are found primarily inside the macula and need a lot of light in order to function. As you go away from the fovea, the number of cones decreases and the number of rods increases. The total number of rods in the entire retina is about 100 million, and the number of cones is about 6 million. Cones are of three types and can detect one color of light: red, green or blue.

Notice that the rods and cones are in the back layer of the retina. Light must pass through all the nerve cells to reach them. Good thing the nerve cells are transparent! The cells that have pigment (color) in them are **retinal pigmented epithelial (RPE) cells** behind the rods and cones. The pigment absorbs extra light so it doesn't scatter about the retina. The pigmented epithelial cells also nourish and protect the rod and cone cells. These epithelial cells are very unusual because they do not go through mitosis, and must last your lifetime. If they stop functioning you experience **macular degeneration**, which can lead to blindness.

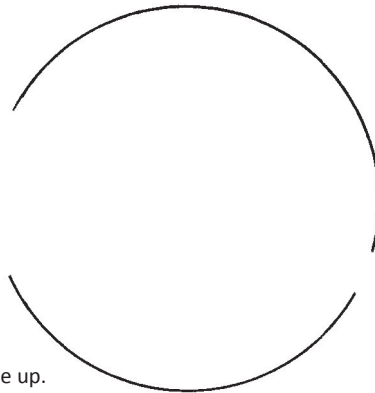
How does the eye focus? The ciliary body controls the shape of the lens.



To focus on distant objects, the ciliary body relaxes, causing the zonules to tighten, making the lens become more flat.




To focus on objects that are close, the ciliary body tightens, causing the lens to become more round.



The image hits the retina upside down.
The brain must learn to see the image right side up.

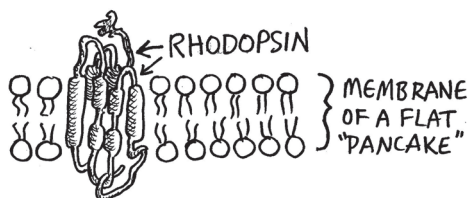
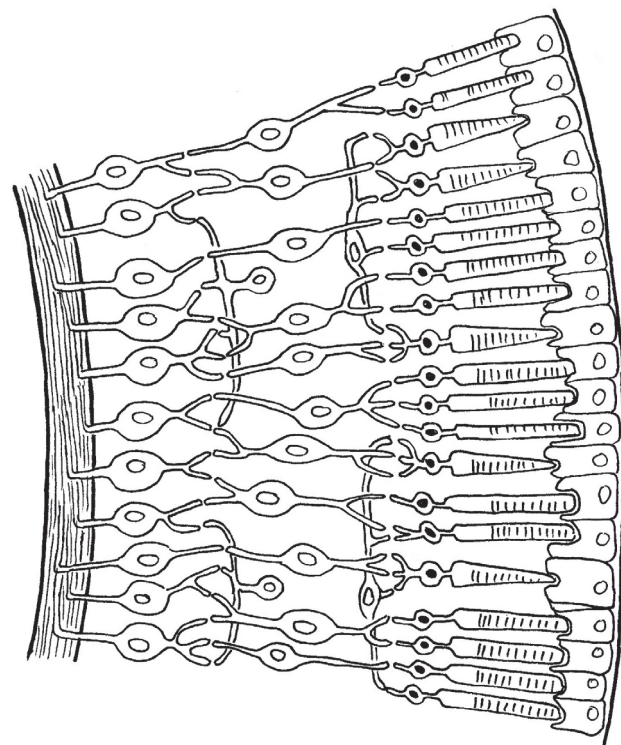
THE RETINA (front view):



HOW THE RETINA WORKS

Rods and cones are backwards from other receptor cells. They are turned on all the time, constantly releasing neurotransmitters. Light actually turns off rods and cones, and prevents them from being active. It is when they stop "firing" that a signal is sent to the bipolar cells.

The mechanism that starts the turning-off process is a pigment molecule called **rhodopsin**. Rhodopsin is found in the phospholipid membranes in the "pancakes" (discs) in the ends of the rods and cones. It holds a smaller molecule called **retinal**. When light hits retinal, its shape changes and this starts a chemical cascade that results in sodium ions rushing into the cell. The influx of sodium stops the cell from releasing its inhibitory neuro-transmitters. The bipolar cells are then activated.



RODS: Cannot sense color, only light/dark. Function in low light conditions.

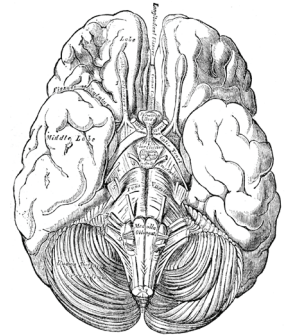
CONES: Sense one of these: red, green blue. Need lots of light to function.

The fovea has about 150,000 cones per mm². Other parts of the retina might have 10,000 or fewer cones per mm².

64: THE BRAIN (part 1)

The brain is the most complex object in the universe. There's no way we're going to learn enough about it in just two lessons. Please feel free to learn more about the brain using books, videos and websites. There's lots of good stuff out there!

From the top, the brain might remind you of a walnut. Both are kind of wrinkly and have two halves, or **hemispheres**. In general, the right hemisphere of the brain controls the left side of the body and the left hemisphere controls the right side of the body. The place where the optic nerves (from the eyes) cross over and go to the other side is clearly visible on the bottom of the brain. This is called the **optic chiasm** (*KIE-az-im*). The crack between the lobes is called the **longitudinal fissure**. (Fissure just means "crack.") The rest of the cracks are called **sulci** (singular: **sulcus**). The lumps and bumps are called **gyri** (singular: **gyrus**). The purpose behind all the wrinkles and bumps is to provide more surface area. Imagine a bath towel lying on a flat surface, then imagine the edges being pushed toward the middle creating many wrinkles and folds. The surface of the brain is called the cortex, and it gets bunched together like that imagined towel so it takes up less flat surface area.



This drawing by Andrea Vesalius in the 1500s shows the brain as seen from the bottom. You can clearly see the nerve chords from the eyes crossing over as they go to the opposite brain hemisphere.

From the side we can see that the brain has three distinct sections. The top part, which we saw in the top view, is called the **cerebrum** (*sah-REE-brum*). It's the part that does all the thinking. However, two other parts are equally important. That little lump under the back of the cerebrum is called the **cerebellum** (*sare-eh-BELL-um*), which means "little brain." This little piece of the brain enables you to coordinate your movements. Without it you could not walk. It also allows you to remember motions like riding a bike, playing the piano, or tying your shoe. The long thin piece going downwards is called the **brain stem**. It looks like it would be the stem if the brain was a flower. The brain stem is where vital functions are controlled, such as breathing and heart rate.

The cerebrum has a notable lobe at the bottom called the **temporal lobe**. It is located behind your ear. This lobe has many important functions including hearing, smell and speech. We'll learn more about it in the next lesson.

If we cut the brain in half lengthwise, making a **sagittal section** (cross section would be ear to ear), we can see most of the internal features. Some of the parts come in pairs, so we have to cheat just a bit. If we went straight down the middle, we'd miss both members of these pairs, so we'll just assume we went a little to one side in order to see one of these parts. We'll discuss each part number by number.

1) Olfactory bulb: There are two of these, one for each sinus. All the sensory neurons lining the inside of the nose connect to the olfactory bulb. (Olfaction is a fancy word for the sense of smell.) The signals travel from the bulb to a location in the temporal lobe where they are interpreted as odors.

2) Pituitary gland: We saw this in a previous lesson. It's tucked into its own little protective bone cavity. The pituitary, pea-sized as it is, has two parts, the anterior and posterior (front and back). The anterior part produces hormones that control many body parts including the thyroid, the adrenal glands (more on both of these in a future lesson), the growth of bones and muscles, reproductive organs in both males and females, and milk production in females. The back part controls the function of smooth muscles in the reproductive organs, plus it sends hormone signals to the kidneys telling them how much water to absorb. The pituitary is directly tied into the hypothalamus and receives signals from its neurons.

3) Hypothalamus: The hypothalamus is right underneath the thalamus. ("Hypo" means "under.") The most well-known functions of the hypothalamus are body temperature and appetite. Without your hypothalamus making you feel hungry you wouldn't know you needed to eat. The hypothalamus is also linked to the pituitary gland, as we saw in number 2. The neurons of the hypothalamus stimulate the cells of the pituitary. This means that the hypothalamus is part of the regulation of all the things that the pituitary does. Additionally, the hypothalamus plays a role in our sleep cycles and even some of our emotions.

4) Thalamus: The this is often described as the "relay station" for all the incoming signals. It has a central location in the brain, which is just where it needs to be to sort out all the signal traffic that is coming in and going out. All the signals collected by your senses go to the thalamus before they go to the brain parts that will interpret them. The thalamus will decide how important each signal is and whether to relay it on to the upper brain. If you are concentrating on something very important, or watching something very exciting, the thalamus might decide you don't need to be bothered with the minor pain signals coming from your skin. Then, later, you'll notice that you injured yourself and think, "When did that happen?" There are limits, of course, and if the pain is great enough, the thalamus will let the signal go through no matter what you are doing.

5) Intermediate mass of thalamus: This is a connecting part and joins the left and right lobes of the thalamus. In this view we can't see the left and right lobes; we see only one. Most brain parts have a left and right section. (The pituitary is an exception.)

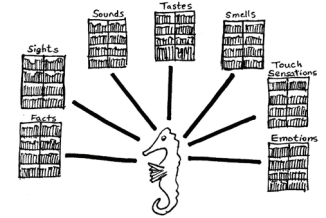
The next four parts form a group called the **limbic system**. This system is your emotional center. Even if you don't think you are a very emotional person, you still have a limbic system. The limbic system also plays a vital role in memory.

6) Fornix: This is a connecting arch that goes up and over the thalamus. (The word "fornix" means "arch.") It connects the mammillary bodies on the front end (anterior) to the hippocampus on the other side (posterior). As with most brain parts, there is a fornix on each side, but they touch in the middle so there can be some communication between left and right sides.

7) Mammillary body: The name of this brain part has nothing to do with its function. It was first discovered well over a hundred years ago, long before anyone had a clue what it did, so they just named it for what it looked like to them, and someone thought that the pair of them looked like mammary glands (i.e. breasts). Yeah, sorry. But they used the scientific name, "mammillary" so it didn't sound so bad. But this part has nothing to do with mammary glands. The clue to its function came from some people who had a nutritional disease that damaged this part specifically. The symptoms of the disease were memory problems. Therefore, it was concluded that the mammillary bodies must play a role in memory. Now the theory is that they act like a relay center, receiving signals from the hippocampus at the other end, and sending some of the signals into a central area of the thalamus. They play an important role in our sense of direction and our memory of places and spaces.

8) Hippocampus: This is at the posterior end of the fornix, and is definitely a huge player in memories. As with the fornix and the mammillary bodies, the name comes from its shape, not its function. Someone thought this part looked a bit like a seahorse, and "hippocampus" is Greek for either "seahorse" or "horse-like sea monster." (Or, maybe they were thinking of "kampe" which means "caterpillar.") Seahorse is actually a good image to use, because it is about the right size and shape.

The hippocampus is the part that transfers short term memories into long term storage. It also helps to retrieve memories when you want to remember them. It's a bit like a librarian who both puts books into storage and also goes and finds them when needed



9) Amygdala: (*ah-MIG-dah-la*) This is near the hippocampus. ("Amygdala" is Greek for "almond.") The amygdala seems to be involved with strong emotions, especially fear and anger. Brain technology now allows researchers to see which brain parts are working in different situations, and they've been able to watch the amygdala light up when certain pictures or ideas were shown or read to the subjects in the experiment. From this, and from dissection of rat brains (and a few human brains) they've been able to determine that this brain part is involved with negative emotions, that it is different in males and females, and that the two lobes of the amygdala are not identical. The left side can experience either happiness or sadness, and might be a key player in conditioned learning, where you receive either positive rewards or negative punishments. The right side is restricted to anger, fear and aggression and makes sure events that produce these emotions get recorded in the permanent memory. It's part of your survival system to make sure you don't repeat behaviors that led to negative consequences. You never forget traumatic events. (Which is also why this brain part is involved in post-traumatic stress syndrome.)

In early childhood, the amygdala seems to be responsible for the fear that babies experience when they see faces they don't recognize. The amygdala also senses people invading your "personal space." Malfunctions in the amygdala seem to play a role in anxiety disorders and alcoholism. In general, males tend to have larger amygdalas, and their amygdalas take longer to develop than they do in females. Males also tend to have the right side of the amygdala be larger than the left. This is one of the lesser known difference between males and females.

NOTE: A few other parts are sometimes listed as being part of the limbic system, because they are connected to it, such as the cingulate gyrus, or the thalamus.

10) Cingulate gyrus: (*SING-gu-late GIE-rus*) Basically, this part connects the cerebrum to the limbic system. However, it is not merely a connecting piece, but adds functions of its own. It connects all those emotional brain parts with the frontal lobe up in the cerebrum, which is the part where conscious decisions are made. The cingulate gyrus makes sure your frontal lobe is involved in any decisions that are very emotional. You might be so angry that you want to throw your friend out the window, but your frontal lobe says no, that would not be a good idea. The cingulate gyrus seems to be involved in positive things like the emotional bonding that happens between mothers and their babies. Also, it connects our language centers in the cerebrum to these emotional centers in the limbic system, making it possible for you to talk about how you are feeling.

11) Corpus callosum: ("Corpus" means "body" and "callosum" means "thick.") This is the part that connects the left and right hemispheres. It is made of bundles of axons, so it looks white. People who have very severe forms of epilepsy sometimes have to have a cut made down through their corpus callosum, so that seizures cannot travel from one hemisphere to the other. This has allowed researchers to do very interesting experiments, testing what happens when the two hemispheres can't communicate. These people are surprisingly normal and if you met them you would not immediately suspect anything was wrong. The problems are only apparent during particular tasks, like asking the brain to name something they are seeing with only their left eye. (Since the right side of the brain controls the left eye, and the right brain usually doesn't have a speech center, the person will not be able to talk about what he/she is seeing.) The results of these tests have helped us learn a great deal about the different functions of the left and right sides of the cerebrum.

12) Mid-brain: This is a center for connections and reflexes. The connections from the cerebrum to the cerebellum go through this area. Also, the pathways that carry signals from the cerebrum to the muscles are found here. One part of the midbrain makes a neurotransmitter chemical called dopamine which is necessary for transmission of signals to muscles. If these cells stop producing dopamine, the result can be "Parkinson's disease." The midbrain also has our pupillary reflexes (adjustments for bright or dim light) and the automatic focusing feature of the lens. The midbrain also seems to play a role in maintaining consciousness (being awake and alert). Some people include the colliculi (16) as part of the midbrain.

13) Pons: ("Pons" means "bridge.") This looks like a lump at the top of the brain stem. It has a number of different functions, but the most well-known of these is the sleep cycle, sometimes called the "circadian (*sir-CADE-ee-an*) rhythm." Your pons will wake you up eventually, even if your alarm clock doesn't go off. The type of sleep that produces dreams seems to originate in the pons. Several very large nerves come out of the pons area, and connect to various parts of the face, eyes, and ears.

14) Medulla oblongata: This long (oblong) part is in charge of keeping us breathing and keeping our heart beating. Our breathing and heart rate keep going while we are asleep thanks to our medulla oblongata.

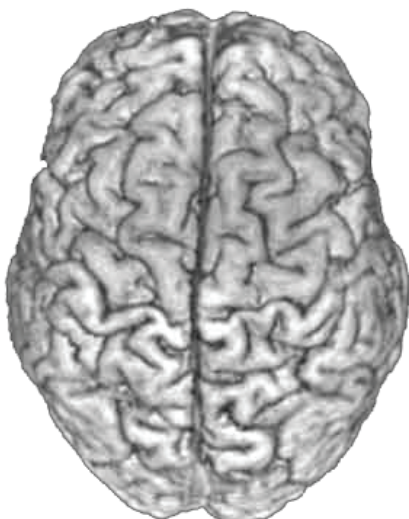
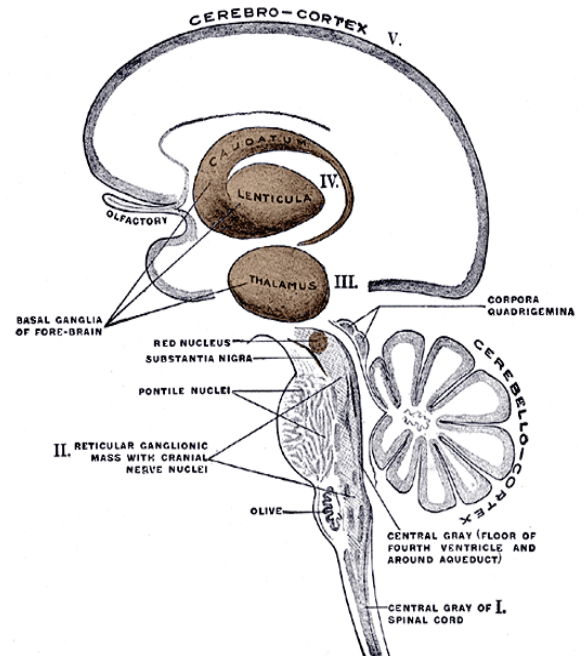
15) Pineal gland: This tiny part produces melatonin, a chemical involved in sleep. It is connected to the eyes and receives information about whether it is light or dark (day or night).

16) Colliculus: (*col-LICK-u-luss*) This area has two sections, the superior (upper) colliculus and the inferior (lower) colliculus. The superior part has important eye reflexes, such as being able to maintain our fix on an object while turning our head. The inferior part is connected to the ears and contains our startle reflex.

NOTE:

There's still one group of brain parts not included on this diagram. There are four places on the inside the cerebrum, kind of around the outside of the thalamus, where there are clusters of nerves, called ganglia. Since these clusters occur generally in the lower half, or underneath, the cerebrum, they are called the **basal ganglia**. They are harder to understand and harder to draw than the 16 brain parts in this lesson, and they are often not shown on brain anatomy diagrams for beginners.. This drawing is pretty full of brain parts already, so I thought it best not to include them.

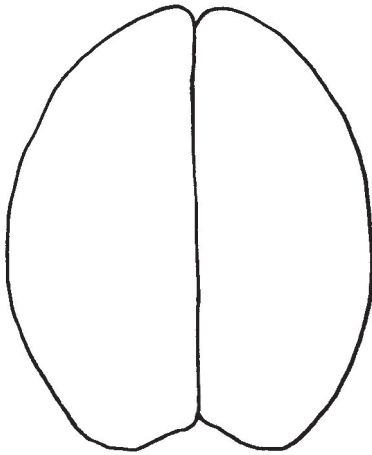
The basal ganglia are coordinating areas that interconnect different parts of the brain. Some of the ganglia help to coordinate muscle movement. There are several neurological diseases that affect the basal ganglia, including Parkinson's disease and Tourette's syndrome. Both disorders involve muscles moving too much, out of the person's control. Tourette's syndrome also has a behavioral aspect, as people with Tourette's sometimes do things that are viewed as socially unacceptable, such as yelling or biting.



Top view of the cerebrum

The brain is extremely complicated. All these drawings and labels have been simplified. If you want more detailed information, the Internet can provide plenty. (There are dozens of small parts and connecting pieces with long Latin names.)

TOP VIEW


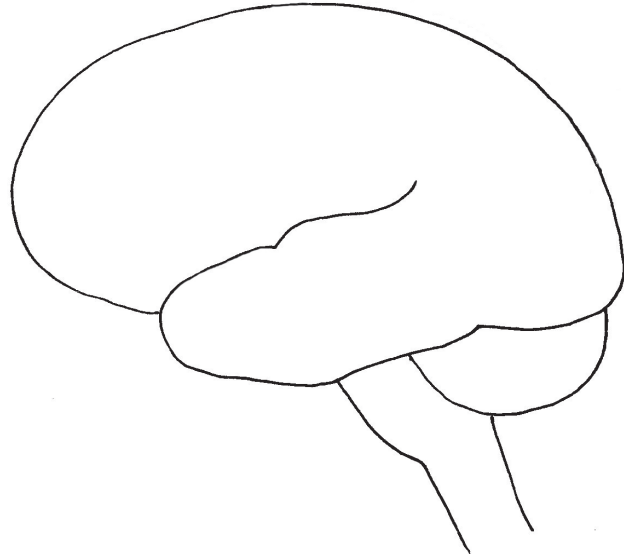


The **LEFT** hemisphere controls the right side of the body.

The **RIGHT** hemisphere controls the left side of the body.


SIDE VIEW

The purpose of wrinkles is to provide more surface area. The surface is where all the neuron cell bodies are and where most of our "thinking" takes place.



CLOSE-UP of protective layers

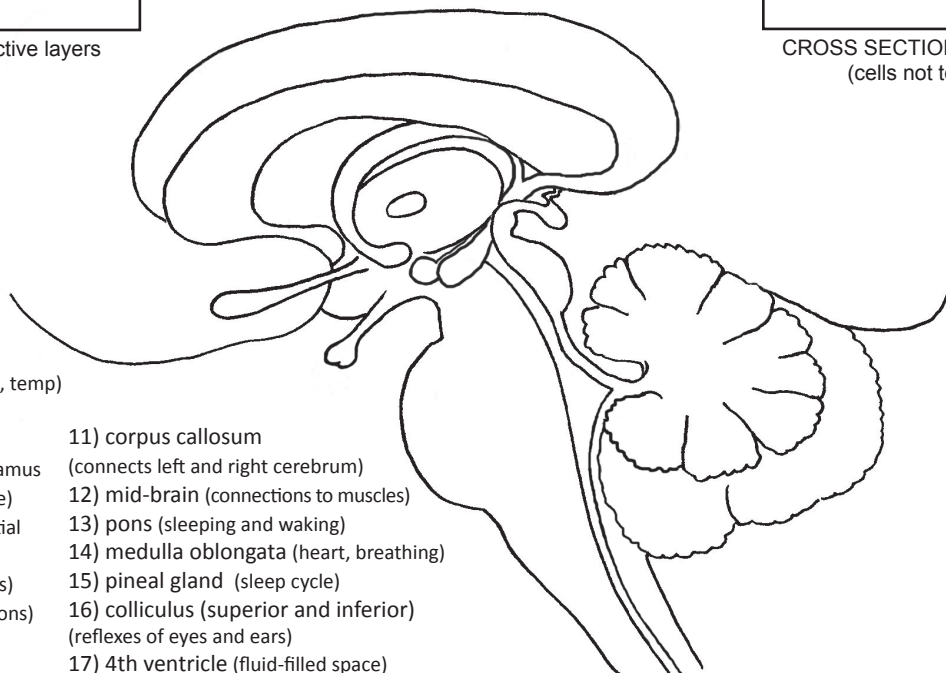
SAGITTAL SECTION



CROSS SECTION of cortex
(cells not to scale)

- 1) olfactory bulb (smell)
- 2) pituitary (growth and reproductive hormones)
- 3) hypothalamus (appetite, temp)
- 4) thalamus (sorts signals)
- 5) intermediate mass connecting two sides of thalamus
- 6) fornix (a connecting piece)
- 7) mammillary body (spatial memory, sense of direction)
- 8) hippocampus (memories)
- 9) amygdala (strong emotions)
- 10) cingulate gyrus (connects top to bottom)

- 11) corpus callosum (connects left and right cerebrum)
- 12) mid-brain (connections to muscles)
- 13) pons (sleeping and waking)
- 14) medulla oblongata (heart, breathing)
- 15) pineal gland (sleep cycle)
- 16) colliculus (superior and inferior) (reflexes of eyes and ears)
- 17) 4th ventricle (fluid-filled space)



65: THE BRAIN (part 2)

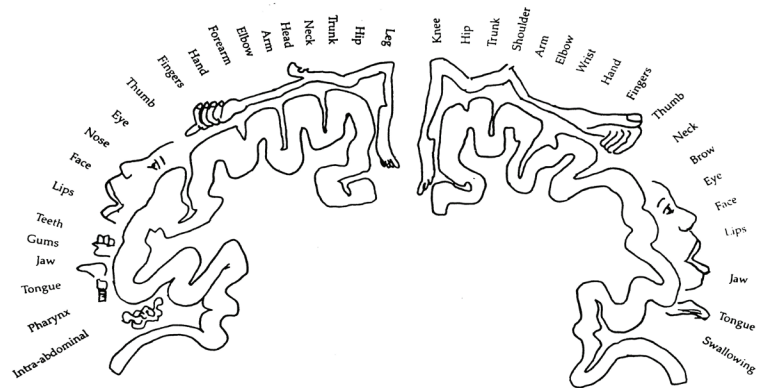
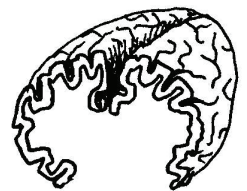
We saw in the last lesson that the cerebrum is divided into two hemispheres, connected by the corpus callosum. Each hemisphere has subsections called lobes. One of the lobes, the *temporal lobe*, is clearly visible, with a sulcus dividing it from the rest of the cerebrum. The other lobes can't actually be seen. We only know about them because of many years of brain research. For over a century, researchers have been carefully documenting brain diseases and making notes about what areas of the brain are affected. Modern brain imaging has added even more information. We can now make a "map" of the brain showing each area and labeling its functions.

1) Temporal lobe: This area has many functions. The centers for **smell** and **hearing** are in this lobe. **Speech and language** are also in this lobe, but usually on just one side. Most people (9 out of 10) have their speech on the left side. The left temporal lobe has sub-sections that specialize in one particular aspect of speech. **Wernicke's area** is where we understand the meaning of sentences. **Broca's area** is where we think of what words we want to put together to make a sentence. The right temporal lobe contributes to speech by adding patterns of rhythm and intonation (voice going up and down).

2) Occipital (ok-SIP-it-al) lobe: This is the area at the very back of the cerebrum. Oddly enough, this is where your vision center is, at the point farthest from your eyes. We've already mentioned that the optic nerves cross over on the underside of the brain so that the left eye connects to the right occipital lobe and the right eye connects to the left occipital lobe. The place where the nerve cross is called the **optic chiasm** (kie-az-im). The occipital lobe interprets the electrical signals coming in from the retina and forms them into an understandable image. Part of this interpretation process includes turning the upside down retinal image right-side up.

3) Parietal (par-EYE-it-al) lobe: This is right above the occipital lobe. The lobe is named after the skull bone (the parietal bone) that covers it. This lobe does many things we take for granted. It is concerned with the perception of space and where our body is in that space. This lobe keeps track of where our arms and legs are, and is the reason we can bring our hands together even if our eyes are closed. The parietal lobe understands the 3-dimensionality of objects and lets us rotate objects in our mind. Interestingly enough, the brain region that Einstein seems to have had more of was the parietal lobe. The ability to visualize math and physics ideas seems to be largely in the parietal lobe.

4) Sensory cortex: This is a thin strip at the top of the parietal lobe where the incoming signals from the body connect to the brain. If you cut a cross section of the cerebrum at this point, it might look something like these diagrams. The top diagram just shows the cerebrum sliced in half. The bottom diagram shows this slice with some body parts and words added to show you how much of this strip of cortex is connected to which parts. The important thing to notice is how much space is devoted to parts of the body that need to be very sensitive, like the fingers and the face. We don't need our feet or our back to be as sensitive as our fingertips. This diagram, with the body parts drawn on it, is often called the "homunculus," meaning "little man," because it looks like a body stretched out. Artists sometimes like to have fun with this concept and draw a person proportioned according to these proportions. Their drawings show people with huge lips, face, hands and fingers and very tiny torsos and legs.



5) Motor cortex: This strip of cortex lies right next to the sensory cortex. This is where the signals leave the brain to go out to the muscles. The "homunculus" of this body part would look very similar to the sensory one, with a lot of nerve fibers going out to body parts that require fine controls such as hands, fingers and mouth.

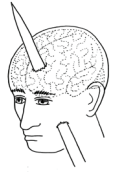6) Frontal lobe: This is the lobe that does the actual "thinking" that the brain is so famous for. This is where we do mathematical calculations, think of stories to write, decide what to eat for breakfast, solve logic puzzles, and ponder our existence. The left and right frontal lobes have slightly different functions, with the left side being more logical and analytical, and the right side more creative and intuitive. Here are typical lists of left/right brain features:

LEFT HEMISPHERE: logic, analysis, sequencing, keeping track of time, names, symbols, computation, moral decisions

RIGHT HEMISPHERE: creativity, intuition, music, art, sculpting, understanding things as a whole, flashes of insight ("Eureka!")

Many lists also include speaking and writing as a left brain activity, but we already mentioned this in the paragraph on the temporal lobe. (And we need to remember that 10% of the population have their speech on the right side, not left.)

Our personalities are to a large degree determined by our frontal lobes. Scientists first learned this through a famous accident. In the year 1848, an American man named Phineas Gage was working on laying railroad tracks when an explosion caused a long metal bar to be blown right up through his skull, passing through his left frontal lobe. Amazingly, he survived this event, but afterwards his personality changed for the worse. Before the accident he was cheerful, honest and hard-working. After the accident he became angry, irresponsible and lazy. This was a good indication that the left frontal lobe plays an important part in personality, especially our moral decisions. (His skull and the metal pike that went through it have been preserved and are now in a medical museum at the Warren Anatomical Museum in Boston, Massachusetts.)



MEMORY

How are living cells capable of forming permanent memories? What actually happens in the cells? The biochemical mechanisms of memory have not been fully discovered yet. (In other words, we don't know!) Some research seems to indicate that there are permanent changes made in the synapses between some neurons, causing them to form strong connections. Tiny "spines" on the dendrites seem to play a part in these synapse changes. Other research points to changes in the cytoskeletons of neurons, and their possible role in making permanent changes inside the cells. In 2017, researchers in Norway discovered that the dendrites and cell bodies of neurons are covered with a thin protective covering made of sugars. If this covering is removed, long term memories are erased. (Don't worry, they only did this to rats who had long term memories of blinking lights.) These are all clues, but we really don't know the whole story yet.

Though the cellular level remains largely a mystery, we are slightly more knowledgeable about the way memories are shifted around in the brain, from short term to long term. We know that ALL memories start out as very short term impressions brought in by our senses. These impressions of sight, smell, hearing, taste or touch, only last for a few seconds, and your brain can only keep track of about 12 of them at a time. They come into our thalamus area to be sorted, and the important ones are then sent into short term storage. The impressions that the thalamus decides to ignore are erased and disappear forever. We could think of many examples of details about life that our brain often ignores: the color and shape of each car we pass in traffic, the location of all the clouds in the sky above us, the type of shoe each person in our class is wearing, the faces of people we see in crowds, all the individual bird songs we hear while hiking, what last month's news headlines were, etc. Life is full of details that we really don't need to remember.

After sensory impressions are sorted by the thalamus region, the important ones are made into short term memories and stored in the very front of the frontal lobe, in an area known as the **prefrontal cortex**. This short term memory area can only hold about 7 items. (Even if you are a super genius, your short term memory still only holds about 7 items!) It's like a temporary "clipboard" and is constantly erased and reused about every 10 seconds. If a short term memory is important, it needs to be turned into a long term memory. The hippocampus takes the information from the short term storage area and transfers it into the neocortex, that outer edge (gray matter) of the cerebrum. Some short term memories are eventually erased after days or weeks or months, but others persist for years.

Quite unexpectedly, researchers discovered that long term memories are not stored all in one place. Each memory is broken up into its sensory components, such as sight, sound, smell, and emotion, and stored as these individual parts. When you want to recall that memory, the hippocampus finds all those pieces—what you saw, what you heard, what you felt about the situation—and reassembles them back into the whole memory. When you are done remembering, it puts them back again. Unfortunately, this is not a perfect process and each time you recall the memory, small changes occur. After a long period of time, our memories can fade or can change significantly. However, if strong emotion was involved at the time the memory was made, and therefore the amygdala played a role, the memory will be encoded much more strongly and will be less likely to fade or change over time.

As with many brain parts, the role of the hippocampus in memory has been figured out by studying brains with damage to that part. The first person that scientists were able to study was a patient from the 1960s, known by his initials, "H. M." Surgeons had removed his hippocampus and amygdala, hoping to cure him of seizures. Big oops, though, as they did not realize how important the hippocampus is for forming memories. H. M. became severely disabled, unable to form long term memories.

Perhaps the most famous person with hippocampus damage is Clive Wearing, a British man who caught a virus (in 1985) that went to his brain and destroyed his hippocampus. Clive can no longer form long term memories. He still has short term memory and can remember new facts for about 10 seconds. After that, his "clipboard" resets and he completely forgets. Before he got sick, Clive was a professional pianist and symphony conductor. When he is asked to play the piano, he'll tell you he's never seen one or played one before, but when he puts his hands on the keys, he'll start to play tunes that he had memorized before his illness. Those muscle memories are in his cerebellum, not his cerebrum, and are not dependent on the hippocampus. Because of his cerebellum memories, he can also remember how to get dressed, shave and brush his teeth, ride a bike, and things like that. (You can find Clive's story in several documentaries posted on YouTube.)

Memories that involve learning facts are called either **declarative** or **explicit** or **procedural** memories. (The terminology in memory science is not standard. You'll find different names for the same things.) Memories that involve moving body parts (dance steps, sports skills, handwriting, etc.) are called either **non-declarative** or **implicit** memories. The first type is stored in the cortex of the cerebrum. The second type is stored in the cortex of the cerebellum.

VENTRICLES

The brain has "empty" places called **ventricles**. These are fluid-filled spaces that help to cushion and protect the brain, as well as providing nutrients to brain cells around the outside of the ventricles. When we did lesson 51, on nerve tissue in the CNS, we **ependymal** (*e-PEND-i-mal*) **cells** forming a lining on the inside of these ventricles. These ependymal cells produce **cerebrospinal fluid**, or CSF. This fluid drains from the ventricles in the brain, down through a canal inside the spinal cord. The canal goes all the way down the spine to the "tail bone" at the bottom. Doctors can take a sample of this fluid by putting a needle into the spine, between two vertebrae bones. This is called a **spinal tap**. By testing this fluid they can learn about problems in the brain, especially infections.

There are four ventricles. The first two are called **lateral** ventricles, with one ventricle in each hemisphere. The **third** ventricle is in the middle beneath the laterals. We labeled the **fourth** ventricle in the last lesson. It is down near the cerebellum. The tube that goes from the 3rd ventricle to the fourth ventricle is called the **cerebral aqueduct**. (Aqueducts were stone water troughs built by the Romans to bring a water supply into a city.) The canal that drains down from the fourth ventricle is called the **central canal**. It goes all the way down to the tail bone. At the bottom of the canal, the CSF will be reabsorbed back into the bloodstream.

When the CSF flows into the fourth ventricle, it can take another route, besides going down into the central canal. It can go through canals that will take it up and around the top of the cerebrum. It flows through a space right under the arachnoid layer, called the **sub-arachnoid space**. From there it will be reabsorbed back into the bloodstream, as osmotic pressure pushes it into the tiny veins that run along the outside of the brain. These veins will eventually drain down into the large **jugular** vein in the neck.

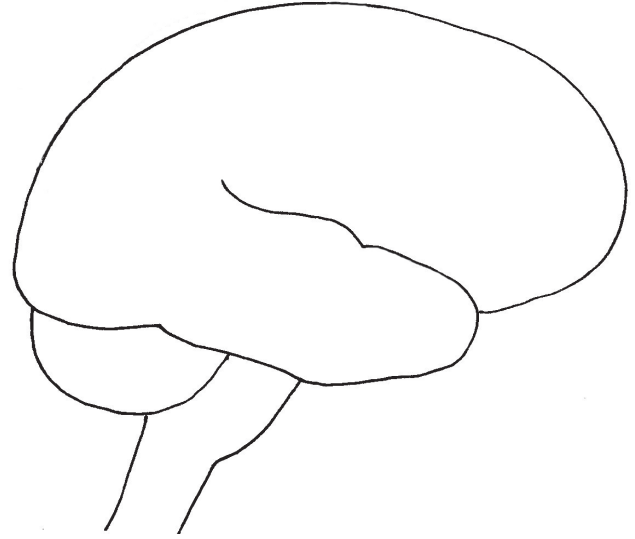
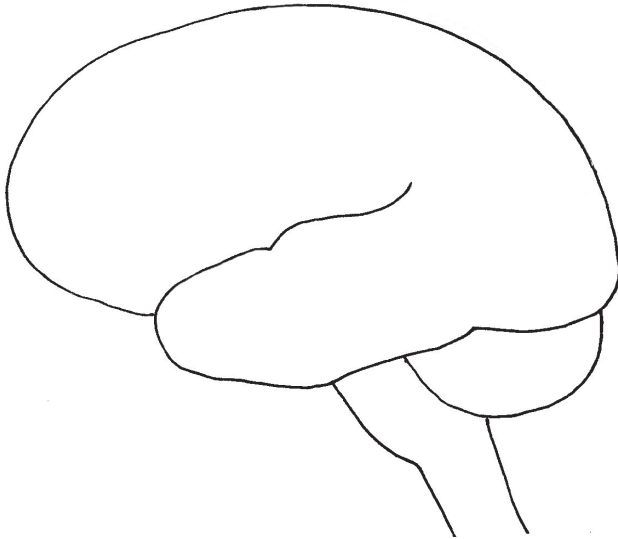
Ventricles were first discovered by someone who poured hot wax into a cow brain, then removed the brain to see what shape the wax had cooled into. He found that there were very well-defined areas, with lobes on each side. Further research found that all mammal brains have ventricles, including human brains.

The LEFT hemisphere is known for:

- | | |
|----------|----------|
| 1) _____ | 4) _____ |
| 2) _____ | 5) _____ |
| 3) _____ | 6) _____ |

The RIGHT hemisphere is known for:

- | | |
|----------|----------|
| 1) _____ | 4) _____ |
| 2) _____ | 5) _____ |
| 3) _____ | 6) _____ |



HOW SOME MEMORIES ARE ENCODED:

(This would be declarative/explicit memories.)

Short term involves glutamate crossing synapses.

Long term involves production of new spines on dendrites.



NOTE: Other types of memory are stored in the cerebellum or the temporal lobe.

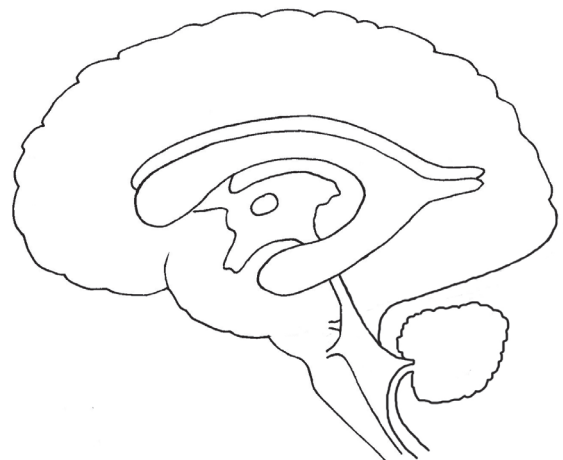VENTRICLES:

Ventricles are filled with cerebrospinal fluid (CSF).

Ventricles and CSF help the brain by providing:

- | |
|----------|
| 1) _____ |
| 2) _____ |
| 3) _____ |
| 4) _____ |

CSF is found in the 4 ventricles, as well as under the arachnoid layer around the exterior. The CSF circulates around these spaces, then drains either into veins at the top and middle of the brain, or down into the central canal that goes into the spinal cord.



CHOROID PLEXUS: epithelial cells that produce CSF

66: BLOOD VESSELS

We've seen blood vessels in a number of places already, but this lesson will focus on the vessels themselves. There are three types of vessels: arteries, veins, and capillaries. Arteries are defined as any vessels that carries blood away from the heart. Veins are vessels that carry blood toward the heart. Microscopic capillaries are the "in between" places where arteries turn into veins.

Both veins and arteries have the same three-layer structure. The inner layer is called the **tunica intima** and is made of another three layers: a layer of epithelial cells (the endothelium), basement membrane (which is under all epithelial cells), and then an elastic layer. The middle layer is called the **tunica media** and is made of smooth muscle surrounded by an elastic layer. The outer layer, the **tunica externa**, or "adventitia, (*ad-ven-TISH-ah*), is made of elastic connective tissue that is also strong. Since fibroblasts make collage and elastin, you will find fibroblasts in this outer layer. Macrophages also can be found in this outer layer.

Arteries are built for high pressure. Since they carry blood away from the heart, they must withstand the forceful pumping of the heart's strong muscles. The muscle layer is very thick, allowing the artery to contract a bit every time the heart pumps. This contraction compensates for the increased pressure in the vessel. The pressure needs to be high, though, so that the blood will keep flowing in all the vessels. (If you laid all your blood vessels end to end, you could circle the globe several times!) Arteries get more muscular as they get smaller. Sometimes large arteries are called "elastic arteries" and smaller arteries are called "muscular arteries." When arteries get very small they are called **arterioles**. When arterioles get microscopically small they are called **capillaries**. Small veins are called **venules**.

Capillaries are only slightly larger than a red blood cell. In fact, some capillaries are small enough that the red cells must squeeze to fit through. The red cells can release a chemical messenger called nitric oxide (formula: NO) that causes them to relax and flex so the red cells can squeeze through.

Veins are built for lower pressure. After the blood leaves the bed of capillaries, it is flowing much more slowly. The pressure is low enough that veins have one-way valves to keep the blood from going backwards. (If these valves stop working properly you can get **varicose veins**, a condition where sections of veins will enlarge and become very visible under the skin.) We met similar one-way valves in the lymph system. Veins have a larger **lumen**, or interior space, than arteries do. Veins have less smooth muscle, but they still have the same basic three layers: the tunica intima, the tunica media and the tunica externa.

Macrophages in the tunica externa of vessels can play a role in the development of a condition called **atherosclerosis**. When damage occurs in endothelial cells, macrophages are attracted to that area to help clean up. In the clean up process they eat fats that are in the area and acquire a foamy texture, giving them the name **foam cells**. Chemical changes result in more macrophages coming to the area and they eat even more fat molecules. Gradually the macrophages die, leaving their remains and all the fat molecules they ate lodged in the wall of the vessel, in the tunica intima. We call this a **plaque**. As long as plaques stay small and stay where they are, nothing too terrible happens. But if they become large they can block blood flow, and if they tear away from the wall of the vessel, they eventually get stuck in a smaller vessel causing a blockage. If the blocked vessel is in the brain we call this a **stroke**. If the blocked vessel is in the heart, it can cause a heart attack. If the blockage is in an arm or leg it can cause a lot of pain and a need for immediate medical treatment. Everyone has atherosclerosis to some degree, as we start forming these plaques even during late childhood. The goal is to keep them to a minimum. Things that help prevent atherosclerosis are not eating too much sugar, eating the right kind of fats (more omega 3 than others), exercising, keeping our weight under control, and not smoking.

Body cells must be near a capillary in order to receive enough oxygen and food. They don't need to be touching the capillary, but they need to be close to it. As red blood cells come through the capillaries, oxygen can be released from the hemoglobin molecules that are carrying them. Oxygen will diffuse to areas that have a low oxygen level. Water can also diffuse out, as well as glucose. Other molecules will go out, also, such as hormones or other chemical messengers. On the other side of the capillary bed, wastes can enter the blood. Once again, simple diffusion is often the way they go in. Wastes that need to be carried away include CO₂, urea, creatinine, and lactic acid. More on these in a future lesson.


Small arterioles can use their smooth (involuntary) muscles to regulate how much blood goes to various parts of the body. If you are digesting food, arterioles in the digestive system can relax and allow maximum blood flow to digestive organs. If you are exercising, arterioles in the muscles will open and arterioles in the digestive tract will shrink. When you exercise, your face gets red because tiny vessels are opening up to help get rid of excess body heat.

There are three types of capillaries. **Continuous** capillaries are the most abundant type and are found most places in the body. Endothelial cells can take nutrients from the blood stream (through endocytosis) and pass them out the other side (through exocytosis) to the waiting body cells. Sometimes things leak through tiny cracks, but the cracks are soon mended. **Fenestrated** cells have tiny holes in them. ("Fenestra" is Latin for "window.") The holes allow a much faster rate of leakage from inside to outside the capillaries. Fenestrated capillaries can be found in the intestines, pancreas, kidneys and in glands. The most leaky type of capillary is the **sinusoidal**, and it is found only in the liver and spleen. These large gaps allow blood cells to exit the capillaries.

There are 3 main types of vessels: **arteries** (away from the heart), **veins** (toward the heart) and **capillaries** (microscopic).


ARTERIES : built for high pressure

The heart is a very strong pump. When blood leaves the heart, it does so under high pressure. Arteries must be able to withstand high pressure. Smooth muscles in the vessels contract with each pump.



VEINS: built for low pressure

Veins experience much less pressure because they are farther away from the heart. In fact, they have one-way valves to ensure that blood does not flow the wrong way.



CAPILLARIES form "beds" (networks)

ARTERIOLE (small artery)

The smooth muscles of arterioles control how much blood goes to which parts of the body.

VENULE (small vein)

TYPES of CAPILLARIES:

1) Continuous

Where? _____

2) Fenestrated ("fenestra" = "window")

Where? _____

3) Sinusoidal

Where? _____

67: THE HEART

The heart is a living pump. It beats about 70-80 times per minute round the clock, not needing to rest like your other muscles do. A heart can pump up to 2,000 gallons (7,000 liters) of blood each day.

When we look at a diagram of the heart we need to remember that the left and right parts are labeled from the perspective of the owner of the heart. Therefore, the left side of the diagram is actually the right side of the heart, and the right side of the diagram is the left side of the heart. (Just imagine the heart inside your own chest think of it from that perspective.)

The heart has four main chambers. The two smaller ones on the top are the **atria** (plural of **atrium**) and the larger ones on the bottom are the **ventricles**. Ventricles have sort of a "V" shape, which makes it easy to remember their name, since ventricle begins with the letter "V." There are valves between the atria and the ventricles. The valve on the right side is called the **tricuspid valve** ("tri" means "three" and this valve has three flap pieces) and the valve on the left side is called the **bicuspid valve** ("bi" meaning "two"). Just to confuse you and make things harder, you also need to know that the bicuspid valve is also commonly called the **mitral valve**. The flaps of the valves are anchored to the ventricles by strings made of connective tissue. (This is perhaps where the term "heart strings" comes from. You may have heard the phrase, "tugging at someones' heart strings," meaning appealing to their emotions.)

The muscle tissue of the heart is called the **myocardium**. ("Myo" means "muscle" and "cardium" means "heart.") This muscle tissue needs its own blood supply so there are arteries and veins on the outside of the heart that go down into the muscles. The muscle fibers of the heart work very hard all the time and need a constant supply of nutrients. If one of these exterior **coronary arteries** or veins gets blocked, those muscle cells will not receive enough oxygen and the result will be a "heart attack."

The heart is actually two separate pumps sitting side by side. The right side receives "used" blood from the body (which contains very little oxygen and a lot of carbon dioxide), then pumps it into the lungs where it gets rid of the carbon dioxide and picks up fresh oxygen. The left side receives the re-oxygenated blood from the lungs and then pumps it out into the body. Blood vessels that are taking blood towards the heart are called **veins**. Blood vessels that are taking blood away from the heart are called **arteries**. Most often we see arteries and veins colored coded with red and blue indicating whether they have a lot of oxygen (red) or very little oxygen (blue). Here in the heart, we find the exception to this color coding rule. We will see veins bringing in blood from the lungs which is rich in oxygen.

The large veins coming into the heart are the **superior vena cava**, the **inferior vena cava**, and the **pulmonary veins**. (The words "superior" and "inferior" mean "top" and "bottom" in this case.) The arteries leading out of the heart are the **aorta** and the **pulmonary arteries**. The aorta has three branches that go off the top, the brachiocephalic ("brachio" means "arms" and "cephalic" means "head"), the carotid (which we saw in the head drawing), and the subclavian ("sub" means "under" and "clavia" refers to the clavicle bone that runs between the neck and the shoulders). After bending over the top of the heart, the aorta then goes down behind it and continues downward, going past the liver and kidneys and then into the legs. (This bottom part is called the **descending aorta**.)

The tip (very bottom) of the heart is called the **apex**. (The word apex is a very common word in science and always refers to the tip of something.) The entire heart is wrapped in a membrane "bag" called the pericardium. ("Peri" means "around" and "cardium" means "heart.") There is fluid inside the pericardium, to allow the heart to move around inside the bag without creating any friction.

When we look at the interior view, we can see these two sides of the heart. The wall between the sides is called the **septum**. The diagram shows the blood from the body coming in through the superior and inferior vena cava and entering the right atrium. When the right atrium contracts, the blood is squeezed down into the right ventricle. As it flows into the ventricle the tricuspid valve opens. After the contraction is over, the valve goes shut, and this is the "lub" sound in the "lub dub" of the heartbeat. The ventricle then contracts and the blood is forced out into the pulmonary arteries where it then goes to the lungs. The valve at the top of the ventricle is called the **semilunar valve**. ("Semi" means "half, or part" and "lunar" refers to the moon. This valve must have flaps that reminded the discoverer of a half moon or perhaps a crescent moon.) When the semilunar valve snaps shut, this creates the "dub" of the "lub dub" sound.

The left side of the heart receives the oxygenated blood from the lungs through the pulmonary veins. (Again, this is why it is helpful to think of the definition of veins as being vessels that go towards the heart, because here we have veins filled with oxygenated blood which would be colored coded as red instead of blue.) The blood comes into the left atrium and then is squeezed through the bicuspid valve (also known as the mitral valve) into the left ventricle. When the left ventricle contracts, the blood goes up through another semilunar valve and into the aorta. The aorta branches off at various points so that blood is equally distributed to all parts of the body. A complete set of contractions—atria and ventricle—is called the **cardiac cycle**.

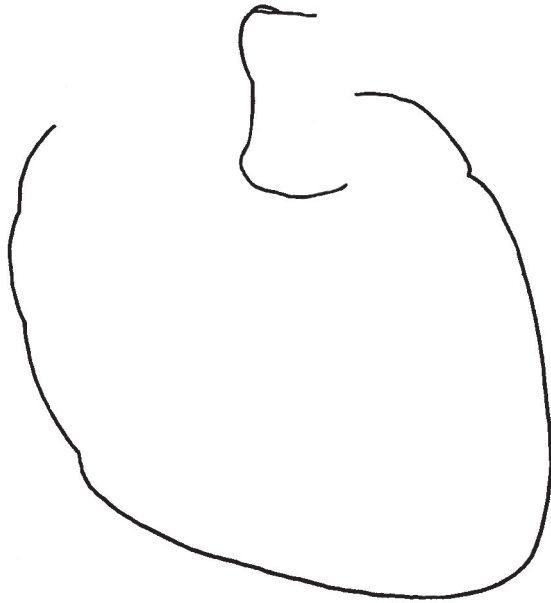
The steady rhythm of the heartbeat is controlled by special nerves in the right atrium. (These specialized cells start working when an embryo is only a few weeks old!) Neurons in an area called the **SA** (sinoatrial) **node** initiate an electrical signal that travels through specialized nerve fibers across to the left atrium. Thus, when the SA node gives the signal, both atria contract together. The signal also travels to another little spot of specialized cells called the **AV** (atrioventricular) **node**. When the AV node receives the signal, it relays the signal through nerve fibers that run down through the septum and out to the walls of the ventricles. This signal causes the muscles of the ventricles to contract. The timing of all of this works out just perfectly, and the ventricles contract a split second after the atria, resulting in a steady pumping motion. These nodes form the **intrinsic conduction system**. (Intrinsic just means internal.) The heartbeat is also influenced by the **extrinsic** (external) system, with the nodes being influenced by signals from the brain or by hormones released by various body parts. When you exercise, for example, your heart rate goes up as the brain signals it to speed up. When you sleep, your heart rate slows down, as your brain stem gives it signals to relax. A sudden jolt of adrenaline from your adrenal glands will cause your heart to start thumping fast and hard. (We'll take another look at these "speed up" and "slow down" control systems when we do an overview of the entire nervous system.)

THE HEART

67

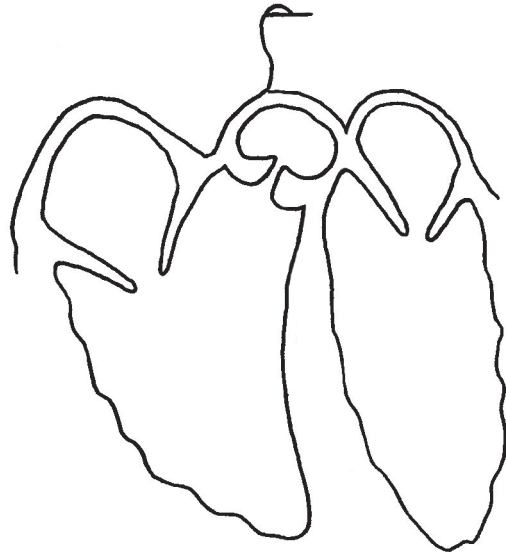
ARTERIES go away from the heart. VEINS go toward the heart.

EXTERIOR ANATOMY



The **pericardium** is a membrane "bag" that goes around (peri) the heart (cardi).

INTERIOR ANATOMY

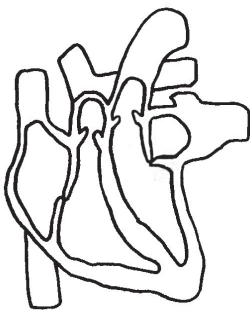


VALVES:

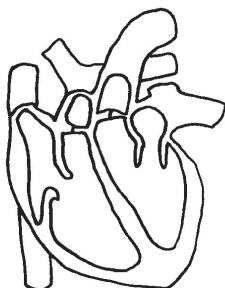
- 1: Tricuspid
- 2: Bicuspid (a.k.a. mitral valve)
- 3: Semilunar valves

"LUB DUB" (the cardiac cycle)

The familiar "lub dub" sound of a beating heart is made by the valves opening and closing.



The first sound, the "lub," is when the cuspid flaps close.

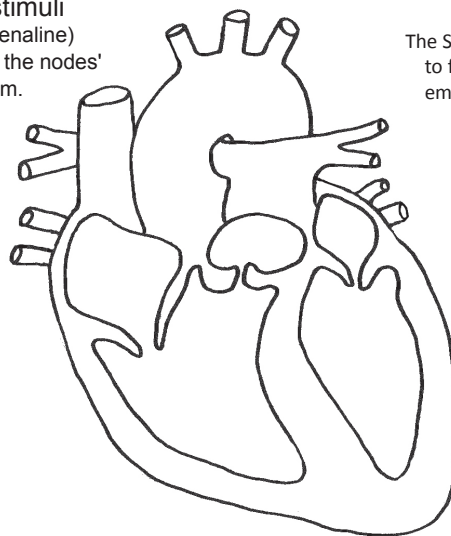


The second sound, the "dub," is when the semilunar flaps close.

Intrinsic Conduction System

(how the heart beats in rhythm)

Extrinsic stimuli (such as adrenaline) can override the nodes' normal rhythm.



The SA and AV nodes began to function very early in embryonic development. An embryo's heart cells begin beating in rhythm long before the shape of the heart has been completed.

The two phases of rhythm:

- 1) _____:
- 2) _____:

68: THE LUNGS

The lungs surround the heart. (The pulmonary arteries and veins of the heart don't have far to travel to get to the lungs!) The heart leans to the left just a bit, so the left lung is slightly smaller than the right lung in order to make space for the heart. The lungs are made of large sections called **lobes**. The right lung has three lobes, the superior, the middle and the inferior, and the left lung has just two lobes, the superior and inferior. Each lobe is made of many smaller lobes called lobules. Each lobule consists of a group of tiny hollow spheres called **alveoli** (*al-VEE-oh-lie* or *al-vee-OLE-ie*). (Alveoli is plural, alveolus is singular.)

The tube that leads down into the lungs is called the **trachea** (*TRAY-kee-uh*). The trachea has rings of stiff cartilage that keep it from flattening. If the trachea was soft and pliable like the esophagus, we would be in constant danger of it collapsing and closing. The cells that line the inside of the trachea are columnar epithelial (lesson 31) and many have cilia on the top. These cilia beat in rhythm to move mucus upward, helping to clean out dust and dirt. The mucus is made by goblet cells. When you cough or clear your throat, the mucus that has been brought up will then be swallowed and go down into the stomach where strong acid will kill most germs.

The trachea branches into two **bronchi** (*bron-kie*), one for each lung. These two tubes are called the primary bronchi. Each primary bronchus then branches into many smaller bronchi, called the secondary bronchi. The smaller secondary bronchi branch into even smaller **bronchioles** (*BRON-kee-oles*). The bronchioles get smaller and smaller until they are almost microscopic. At the end of each tiny bronchiole is a lobule made of alveoli. The alveoli are wrapped in microscopic capillaries, and this is where gas exchange happens. The endothelial cells of the capillaries lie right next to the very flat squamous cells of the alveoli. In this way, the blood gets so close to the air inside the alveoli that oxygen and carbon dioxide can diffuse in and out of the blood. This is classic diffusion at work (lesson 6). Gases will diffuse from places where there is more to places where there is less.

The blood in the capillaries has come to the lungs to pick up oxygen, so it has a low level of oxygen. Oxygen from the air will pass right through the alveolar epithelial cells and the endothelial cells, and into the red blood cells. In the red cells, the oxygen attaches to a heme molecule that is being held by a hemoglobin molecule (lesson 39). The oxygen will ride on the heme until it reaches a place where there is less oxygen outside the capillary, and then it will be released to into the tissues that need it.

Carbon dioxide is brought into the lungs as waste that needs to be disposed of. (CO_2 was created in the cells as a by-product of cell processes, and it passed into the blood via diffusion.) CO_2 is carried in the blood in three ways. First, a small amount can simply dissolve into the water of the blood plasma. Second, another small amount can attach to the globin (protein) part of hemoglobin. Third, most of the CO_2 is carried in the plasma not as CO_2 gas but as bicarbonate ions: HCO_3^- . How does this happen? The CO_2 goes into the red blood cells where a special enzyme combines CO_2 and H_2O to make carbonic acid, H_2CO_3 . You may remember from previous lessons that when you see " H_2 " at the beginning of a molecule, it is likely to be an acid. You might also remember that one of the H's often goes wandering off, leaving its electron behind. The negative sign at the end of the molecule represents this electron. Wandering H's are hydrogen ions, shown as H^+ . The hydrogen ions bind to the hemoglobin but the bicarbonate ions (HCO_3^-) diffuse out of the red blood cell and into the plasma. All these negative ions diffusing out could create pH problems for both the red blood cell and the plasma, so an exchange is done where Cl^- ions diffuse into the red cell to replace the bicarbonate ions that are diffusing out. The bicarbonate ions ride along in the blood until they reach the lung, when this process is reversed and the bicarbonates are turned back into carbon dioxide gas that can be exhaled by the lungs.

The alveolus is lined not only with very flat squamous cells, but also cuboidal cells that secrete a special fluid. This fluid consists of water with some very particular proteins and phospholipids. The tails on these phospholipids are both palmitic acid, which we saw in a list in lesson 3. This fatty acid is just the right one for this job. The phospholipid lies on the surface of the water with one tail in the water and one tail sticking up into the air. When you get a whole bunch of these phospholipid head and tails floating on the water, the water molecules are not able to hang together as tightly as they usually are. The result is that gases, like oxygen, can dissolve into the water much more easily. As chemical that reduces surface tension of water is called a surfactant. If the lungs did not produce surfactant along with the secreted water (which must be there to keep the lungs moist), we would not be able to get enough oxygen. Also, the surfactant affects the ability of the alveoli to pop back open after the collapse a bit during exhaling. So there are two reasons we must have this surfactant in that fluid. Developing babies do not begin to produce large quantities of surfactant until the end of the 8th month of pregnancy. This is the most common complication with premature births. The babies must be on breathing equipment that supplies not only extra oxygen but also artificial surfactant.

Special macrophages called **dust cells** (lesson 42) crawl around on the inside surfaces of the alveoli, cleaning up dust, dirt, debris from dead cells, bacteria, fungi and viruses. They do a great job of keeping the lungs clean. Problems arise, however, when they are faced with things they cannot digest, such as asbestos.

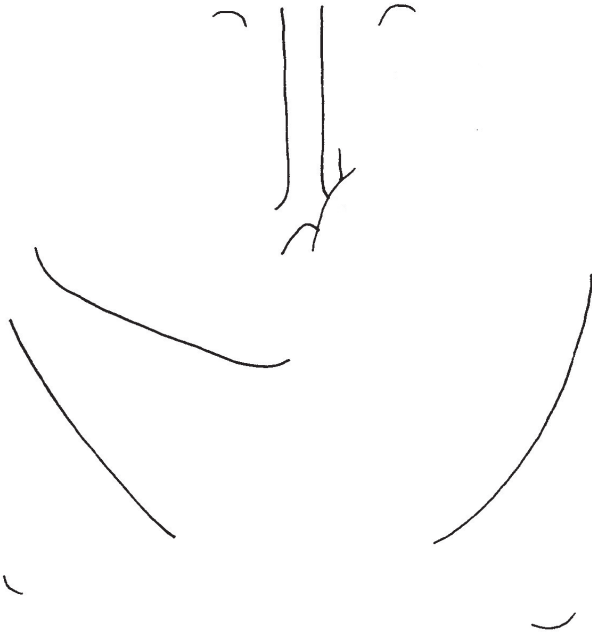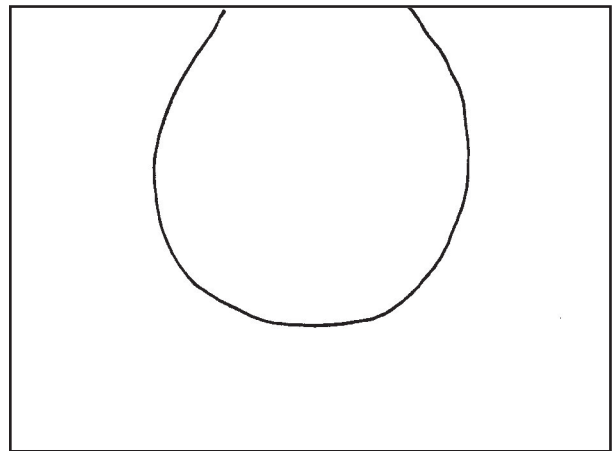
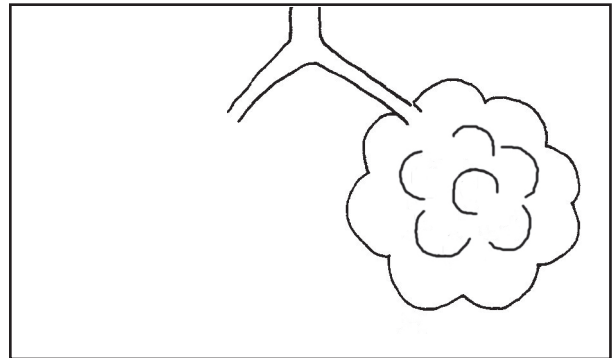
Creating a "wall" underneath the lungs and heart is the **diaphragm**. This muscle is shaped like an upside down bowl, and forms a barrier between the thoracic (*thor-ass-ick*) cavity above, and the abdominal cavity below. There are only three places where things connect these two cavities: 1) the inferior vena cava, 2) the descending aorta, and 3) the esophagus. The diaphragm muscles are connected directly to the medulla oblongata in the brain stem (lesson 64). The medulla is able to sense when the CO_2 levels are too high and it sends a signal to the diaphragm (and to the intercostal muscles between the ribs) to contract. When these muscles contract, the result is that the chest area expands. The expansion causes the air pressure inside the lungs to fall, and more air rushes into to fill this area of low pressure. The **serous membrane** "bags" that surround the lungs (**parietal pleura** (*plur-uh*) on the outside and **visceral pleura** on the inside) have a thin layer of liquid between them (serous fluid) that creates suction (like when two plastic cups get stuck together) and this section plays a role in the action of inhalation. The outer (parietal) layer is attached to the wall of the thoracic cavity so when the chest expands with the action of the diaphragm, the inner (visceral) membrane gets pulled along, too, thus opening the lungs.

Although the lungs are the main organs of the respiratory system, the action of the lungs is actually called **ventilation**, not respiration. Respiration is what happens in the cells ("cellular respiration" from lessons 18 and 20 in module 1).

When the lungs take in air, this is called **inhalation**. When the lungs expel air, this is called **exhalation**.

The **THORACIC CAVITY** contains the lungs, the heart, the trachea and the esophagus. The **diaphragm** separates the thoracic cavity from the abdominal cavity below.

At the end of each bronchiole is a **lobule** made of microscopic **alveoli**. Each alveolus is covered with a bed of capillaries.



The diaphragm is shaped like an upside down bowl.

Three holes in diaphragm:

- 1) inferior vena cava, 2) descending aorta, and 3) the esophagus.

Contraction of the diaphragm causes the chest to expand, causing air to rush in.

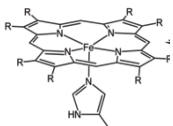
WHAT CAUSES US TO BREATHE:

The diaphragm is "wired" to the medulla oblongata in the brain. The medulla is very good at sensing small changes in the CO_2 level in the blood and sends signals for the diaphragm and the intercostal muscles (between the ribs) to contract when CO_2 gets too high.

- 1) ultra-thin squamous epithelial cells
- 2) cuboidal epithelial cells that secrete **surfactant**
- 3) macrophages called "dust cells"
- 4) layer of water that contains surfactant (phospholipids that lower the surface tension of water so that O_2 can pass through)
- 5) endothelial cells of the capillaries
- 6) red blood cells that pick up the O_2

HOW O_2 IS TRANSPORTED IN THE BLOOD:

RBCs contain billions of hemoglobin molecules.



HOW CO_2 IS TRANSPORTED IN THE BLOOD:

- 1) A small amount is carried by the globin part of hemoglobin, or is dissolved directly into the plasma.
- 2) Most CO_2 is combined with water to form carbonic acid (H_2CO_3), then bicarbonate ions (HCO_3^-) and hydrogen ions (H^+). HCO_3^- diffuses out into the plasma. To keep the pH even, Cl^- ions diffuse in to replace HCO_3^- .

69: THE LIVER and GALL BLADDER

The liver is the largest gland in the body. A gland is defined as something that secretes one or more substances that are useful to the body. As we will see, the liver is the ultimate gland, as it secretes more different types of chemicals than any other gland in the body. The liver of an average-sized adult weighs about 3 pounds (1.5 kg). Human livers are the same color as those chicken livers you see in the grocery store (a reddish brown) and have a rubbery texture.

Both the liver and the stomach lie right below the diaphragm. In the last drawing we saw that the diaphragm has three holes in it: for the inferior vena cava, the descending aorta, and the esophagus. The esophagus leads to the stomach, and we will learn more about it in the next lesson. Both the inferior vena cava and the descending aorta connect to the liver. The aorta brings oxygen-rich blood into the liver. The blood that the vena cava transports into the heart is low in oxygen but it is rich in nutrients, as we will see.

The blood supply to the liver comes from two sources: from the descending aorta, as we just mentioned, and also from veins called the **hepatic portal veins**. (Words that begin with "hep" or "hepa" always have something to do with the liver. "Hepatic portal" might be translated as "doorway in the liver.") The blood in the hepatic portal veins comes from several sources: from the spleen, the pancreas, the stomach, and the intestines. Basically, all of the blood from the abdominal cavity (everything below the diaphragm) comes into the liver through these portal veins. This means that before any nutrients from food are distributed to the body, they must go through the liver first. The liver keeps track of how much sugar and fat are in the blood and will do its best to prevent an overload of either one. For example, if the glucose level in the blood is too high, the liver can start catching and storing the extra glucose molecules, putting them into long strings called **glycogen**. (We also find glucose stored as glycogen in muscle tissue.) About 5 percent of the liver's weight is glycogen.

Between meals, your liver is constantly checking the blood's glucose level and when it begins to fall below about 70 grams per deciliter (a deciliter is one tenth of a liter) the liver will begin to break down some of the glycogen and turn it back into glucose, and release it into the blood. If the liver runs out of stored glycogen and the body still needs more glucose, the liver cells will begin turning amino acids into glucose. Ultimately, all forms of energy (sugar, fats, proteins) must be converted into glucose so that it can be fed into the Krebs cycle and then into the Electron Transport Chain. If the liver runs out of space to store glucose as glycogen, it will then begin turning the glucoses into triglycerides and send them out into the body to be picked up by adipose cells that will store them as fat. The process can go the other way, too, as the liver can turn protein and fat into glucose. This is how carnivores who eat only protein and fat survive. Their livers convert the protein and fat into glucose. This process is called **gluconeogenesis**. ("Gluco" = sugar, "neo" = new, "genesis" = to make) In the process of turning aminos into glucose, the nitrogen part of the amino acid must be discarded, as there isn't any nitrogen in either sugars or fats. The nitrogen from the amino acid is discarded as a molecule of NH_3 , ammonia, a substance that is very poisonous to the body. But the liver has a way to deal with ammonia—it quickly turns it into a molecule of urea, which still contains that nitrogen but is much less poisonous. The urea can safely float around in your blood until it reaches the kidneys where it will be filtered out and then sent out of the body with the urine.

The liver can also turn sugars and fats into amino acids. There are still those 6 "essential" amino acids that your liver can't make and that you must get from your diet, but the rest can be manufactured by liver cells. If you eat too much of one kind of amino and not enough of another, the liver has enzymes that know how to transform one amino into another. Pretty amazing!

Another major function of the liver is to produce **bile**. Bile is a liquid made of water, bile salts (also called bile acids), cholesterol and phospholipids. Bile acts very much like the dish soap you use to cut the grease on your dirty dishes. Bile "emulsifies" fats, meaning it breaks them up into very small pieces. Each tiny bit of fat is surrounded by phospholipids that have their water loving heads facing outwards so that the fat molecules can travel safely in the blood. (The job of the salts/acids is to act as a surfactant.)

The gall bladder is the storage area for bile. When fatty foods reach the **duodenum** (the first part of the small intestine, pronounced either *du-ODD-den-um* or *du-oh-DEE-num*), chemical signals are sent to the gall bladder telling it to release some bile. (In people who have had their gall bladder removed, the bile just flows directly from the liver into the duodenum.)

Other functions of the liver include making and transporting cholesterol using "shuttles" called LDL and HDL. The LDL's are the delivery system taking cholesterol out to the cells. The HDL's are involved in collecting leftovers and returning them to the liver for recycling. (Doctors tell us we want more HDL's than LDL's.) The liver also stores iron (Fe) and fat-soluble vitamins: A, D, E K, plus B12.

A microscopic view of the liver shows that it is made of individual units called **lobules**. Each lobule is approximately in the shape of a hexagon. At the center is a **central vein** that will eventually lead into the hepatic vein that goes up into the inferior vena cava. At each vertex of the hexagon you find a **triad** of three vessels: 1) a hepatic artery, 2) a portal vein, and 3) a **bile canaliculi** (tiny canal). The hepatic arteries contain blood that came in from the descending aorta so they are rich in oxygen. The portal veins contain blood that came in from the veins in the stomach and intestines so they are rich in nutrients. Both the hepatic arteries and the portal veins lead into the central vein. (As with all other blood vessels in the body, they are made of endothelial cells.) The fluid in the bile canaliculi comes from all the surrounding cells, and goes out through larger and large bile vessels until it reaches the **bile duct**. The large "common" bile duct connects to both the gall bladder and the duodenum.

The blood from these tiny portal veins and hepatic arteries joins together in a space called the **sinusoid**. On the walls of this sinusoid space, macrophages called **Kupffer cells** crawl around looking for bacteria to destroy or red blood cells that need to be recycled. It is in the Kupffer cells that hemoglobin is broken down into heme and globin.

The large cells (that are not endothelial cells) are called **hepatocytes**. The hepatocytes have three notable features: 1) a large amount of smooth ER, 2) microvilli (that look like fringe), and 3) occasionally a double nucleus. When cells have more DNA than normal, this is called **polyploidy**. Why many liver cells are polyploid is not yet fully understood. Notice the bile canaliculi between the cells. The hepatocytes do numerous jobs including breaking down toxins such as alcohol, making and monitoring glucose, fats and amino acids (as we've already mentioned), making clotting factors for the clotting cascade (from lesson 38), making blood proteins such as albumen, and making all the immune system proteins that begin with "C" (C-reactive protein and C1 through C9, from lesson 48).

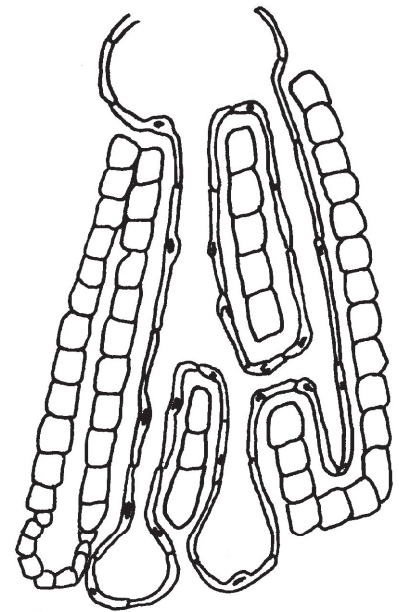
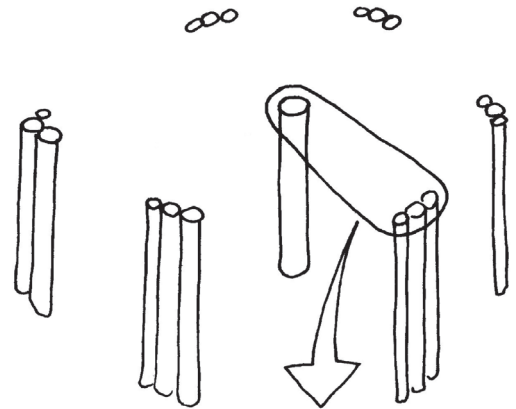
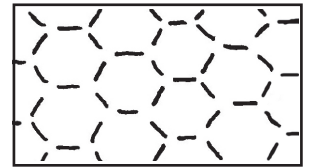
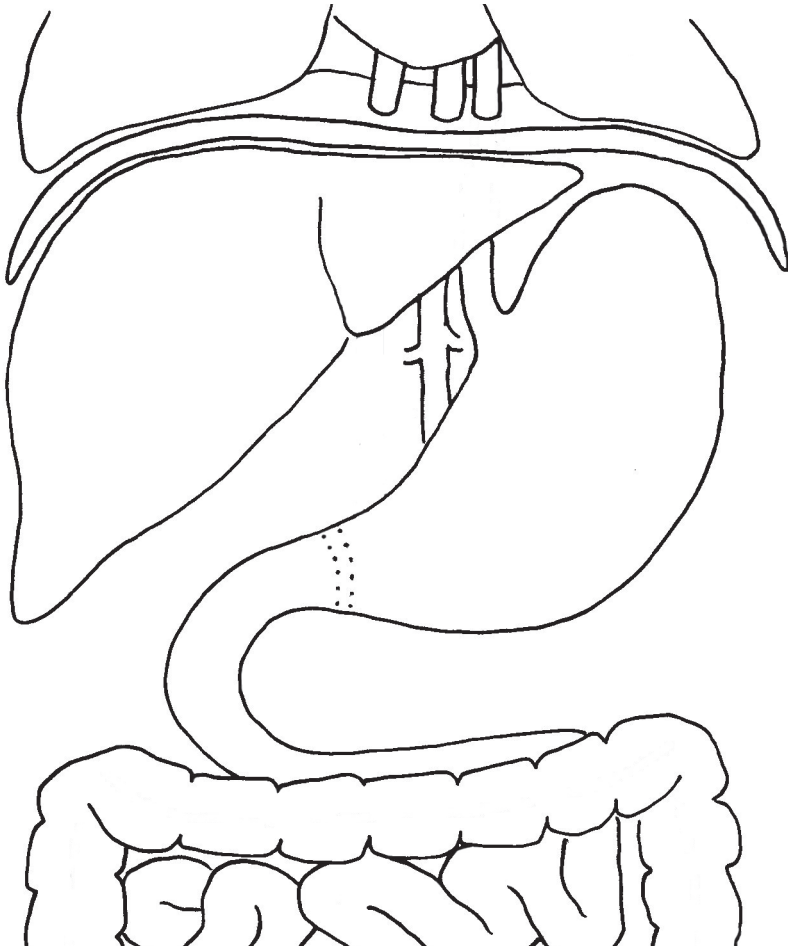
The space between the hepatocytes and the endothelial cells is called the **space of Disse**. Plasma from the blood leaks out into this space, interacts with the hepatocytes along their microvilli, then drains into the lymph system. Stellate cells live in this space; they store vitamins and make the collagen network that holds all the lobule cells in place.

THE LIVER and GALL BLADDER

69

The liver is the largest gland in the body. It weighs about 3 lbs (1.5 kg). It is the ultimate "multit-tasker" and by some counts does as many as 500 jobs! The gall bladder is simply a storage bag for one of the products that the liver makes.

MICROSCOPIC VIEWS:



MAJOR FUNCTIONS of the LIVER:

- A: _____ : _____

- B: _____ : _____

- C: _____ : _____

- C: _____ : _____

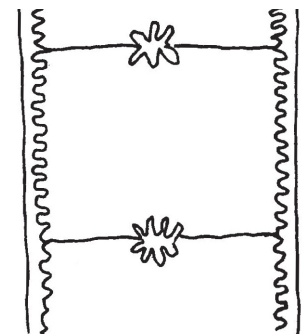
- C: _____ : _____

- D: _____ : _____

- E: _____ : _____

- F: _____ : _____

- G: _____ : _____



70: STOMACH and duodenum

We've already seen how the esophagus pokes down through the diaphragm. In this drawing we'll add a nerve that travels down with it. The **vagus nerve** is the main nerve of the digestive system. The vagus has two branches, left and right, that come down from the brain stem. They go through the diaphragm alongside the esophagus and then they branch off to connect to most of the organs in the abdominal cavity. There are both afferent and efferent nerves in the vagus. Remember, the afferent are sensory neurons and the efferent are motor neurons. The motor neurons control the muscular motions of the digestive organs, most notably **peristalsis**. In peristalsis, the circular and longitudinal muscles coordinate their movement in such a way that the **bolus** (food glob in esophagus) or **chyme** (mush in intestines) is pushed along through the tubes.

Right where the esophagus meets the stomach, there is a ring of muscle called the **esophageal sphincter**. A sphincter (*sfink-ter*) muscle is a special type of muscle that works backwards from regular muscles. In most muscles, the "normal" state of the muscle is relaxed and uncontracted and the action of the muscle is to contract. In a sphincter muscle, the "normal" state is contracted and to use the muscle it must be relaxed. Sphincters come in very handy in places in the body that require keeping something in. If we did not have a sphincter at the very end of our digestive system, for example, our feces (poop) would just plop right out all the time. The sphincter holds everything in until we are able to visit a bathroom. The stomach has two sphincter muscles, one at the top and one at the bottom. The esophageal sphincter prevents the highly acidic stomach fluid from splashing up into the esophagus. When stomach acid gets up into the esophagus we call this **acid reflux**, or "heartburn." The sphincter at the bottom of the stomach keeps food inside until it is adequately churned into a soft mush that can safely go through all the bends in the intestines. Strong muscles in the **pyloric** (*pie-LOR-ick*) region of the stomach push chyme through the **pyloric sphincter** and into the **duodenum**. The duodenum is shaped like the letter C, and connects the stomach to the small intestine. The bile duct is attached here as we saw in the last lesson. The pancreas also has a duct that empties into the duodenum, often connecting to the bile duct.

Food is pushed down through the esophagus by muscle movement called peristalsis. This motion is done by involuntary muscles controlled by the automatic mechanisms in the brain stem. Even if you stand on your head while eating, the food would still go down into the stomach, against gravity, because of the action of the muscles of the esophagus.

The stomach, as you probably know, is a very acidic place. Cells in the lining of the stomach produce hydrochloric acid, HCl. The pH level (on the scale of 1 to 14) is about 2. The acid is what activates a protein digesting enzyme called **pepsin**, also made by the cells in the lining of the stomach. The cells actually make an inactive form of the enzyme called **pepsinogen**, and the acid turns it into pepsin. Remember how fibrinogen was turned into fibrin? A molecule that will turn into an active enzyme is called a **zymogen** (*ZIE-mo-jen*). ("Zym" means "enzyme," and "gen" means "to make.") The body does this to prevent the enzyme from acting too soon or in the wrong place. You don't want pepsin digesting your own cells before it gets to your food, and you don't want fibrinogen turning into fibrin while it is floating around in your blood. Pepsin's job is to break down protein chains into amino acids that can be used by your cells' ribosomes to make their own protein structures.

If we peeled back the outer tissue layer of the stomach we would see three layers of muscles: **oblique** (meaning diagonal), **circular** and **longitudinal**. The combined action of these directional layers produces a churning, mixing motion. Only the stomach has the outer oblique layer. The rest of the digestive system has only circular and longitudinal.

If we look at the inside of the stomach we see deep folds and wrinkles. These folds allow the stomach to stretch and expand as it fills with food. As the stomach stretches, signals are sent to the brain to tell the muscles layers to start churning.

If we take a really close-up look at the stomach lining (under a microscope) we see that the surface is made of tiny finger-like things called **villi**. These are not microvilli, just villi. The cells that form the top of the villus are called **pit cells**, because the spaces between the villi are called **gastric pits**. The pit cells are basically goblet cells that make large amounts of mucus all the time. They coat the surface of the stomach lining with mucus to protect it from all the hydrochloric acid. The bottom half of these spaces between the villi are called gastric glands and they are made of several types of cells. **Parietal cells** are at the top of this gland area, dividing it from the mucus-producing top area. (Parietal means "wall.") Parietal cells make the hydrochloric acid. **Chief cells** make the pepsinogen zymogen that will be activated into pepsin. Chief cells also make a chemical called IF (intrinsic factor) that binds to vitamin B12 to protect it from being destroyed by the HCl. **G cells** make a hormone called gastrin that stimulates the parietal cells. There are also a few **enteroendocrine** (*en-TARE-oh-EN-do-krin*) cells that secrete a number of different hormones that control various aspects of digestion. All these hormones allow for your body to maximize digestive processes and also to adjust to unusual situations such as fasting, over-eating, and illness.

The villi and all their various cell types make what we call the **mucosa layer**. Under the mucosa layer we have the **submucosa**. The submucosa is basically loose connective tissue, with a network of collagen, blood and lymph vessels, and immune cells. We have not drawn the lymph vessels or the immune cells in this drawing, but we will definitely see the lymph vessels in our drawing about the intestines because they perform an important job in digestion. Under the mucosa is the **muscularis** layer, with its bands of smooth muscles going in various directions. Of course, these are not voluntary muscles like we find in our arms and legs. These smooth, involuntary muscles operate all the time with no thought required.

You will notice that there are capillaries running up into the villi. In the stomach, these capillaries can absorb a few things, such as alcohol, but they are not able to absorb most nutrients. Absorption primarily takes place in the small intestines. We will also see in the lesson on the intestines that the villi have microvilli, greatly increasing their surface area.

The digestive organs, including the stomach, are surrounded by an outer layer called the **serosa**. (We saw a serosa layer round the lungs, also.) The serosa is a layer of epithelial cells with a bit of connective tissue underneath. These epithelial cells secrete **serous fluid** which helps to lubricate the outsides of all the organs so that friction is not created when we move and bend our torso.

STOMACH (and duodenum)

70



WORDS TO KNOW:


_____ : a wad of food traveling down the esophagus

_____ : mushy stuff that leaves stomach


_____ : muscular action of the digestive tract to push food along

_____ : a sore in the lining of the stomach

_____ : a "precursor" of an enzyme, meaning an enzyme that has not yet been activated. Examples: fibrinogen, pepsinogen ("zym" meaning "enzyme," and "gen" meaning "to make")



CROSS SECTION:




- (1) _____
 - A) _____ : make mucus
 - B) _____ : make HCl (acid that makes stomach have pH of about 2)
 - C) _____ : make pepsinogen and "IF" factor that protects vit. B12 from acid of stomach
 - D) _____ : make gastrin, a hormone that stimulates parietal cells
 - E) _____ : secrete many hormones that control aspects of digestion

- (2) _____
Loose connective tissue that contains blood vessels

- (3) _____
 - A) _____
 - B) _____
 - C) _____

- (4) _____ : epithelial cells secrete serous fluid for lubrication

CROSS SECTION OF STOMACH WALL:



71: PANCREAS (and digestive enzymes)

The pancreas is classified as a "mixed gland." This means that it functions as both an exocrine gland and an endocrine gland. An **exocrine** gland secretes its products to the outside ("exo" means "out") through some kind of duct or physical opening in the gland. An **endocrine** gland secretes its products directly into the blood via capillaries that come into the gland.

The exocrine part of the pancreas is made of groups of cells called **acini**. These cells cluster together to make sort of "mini-glands" that have ducts in the center. These cells make vesicles filled with zymogens that will go through the duct system and be dumped into the duodenum. The zymogens will be turned into their active forms (enzymes) as they go through the small intestine. Some people have a pancreatic duct that looks like a Y, with each branch of the Y making an opening into the duodenum. Other people have a duct that does not branch and has just one opening into the duodenum. This is because of the way that the pancreas forms during the embryonic stage. It starts out as two separate buds, each with their own duct. At a later stage, these two buds merge together to make one whole pancreas. Sometimes the ducts merge and sometimes they don't.

The most well-known of these enzymes are **pepsin**, **trypsin** and **chymotrypsin**, which all are proteinases that break down proteins. These exocrine cells also make **lipase**, an enzyme that breaks down lipids (fats), and **amylase**, an enzyme that breaks starches down into **maltose**, a disaccharide made of two glucoses stuck together. The cells of the intestines will make maltase, the enzyme that breaks maltose into its two glucose units. Amylase is also produced by salivary glands so that starches begin to be broken down while still in the mouth. Plants also make amylase. For example, when a banana ripens, starch molecules are being broken down into glucose. You can taste this difference if you compare a green banana to a ripe one.

That cover proteins, fats and carbohydrates (starches). What's left? Some food also contains cells that have DNA and RNA in them (plant cells, for example). The pancreas makes nucleases to deal with these. A **nuclease** is an enzyme that works on nucleic acids and takes apart the "rungs" of the DNA and RNA "ladders."

These cells of the acini make another very important product that is not an enzyme. They make **sodium bicarbonate**, NaHCO_3 , which is the chemical we use in our kitchens as baking powder. Sodium bicarbonate is alkaline (basic), the opposite of an acid, so it can neutralize stomach acid. The stomach has that special mucus coating to protect it from its own hydrochloric acid, but duodenum does not have that protection. The acidity of the chyme must be neutralized as it comes into the duodenum. Fortunately, the pancreatic duct opening is right there, squirting in sodium bicarbonate.

The endocrine function of the pancreas is found in little "islands" or "islets" in the middle of the "sea" of acini. The first person to discover them was Paul Langerhans, so they were named **islets of Langerhans**. These little islets are made of about half a dozen types of cells but there are only three that are well-known. The **alpha (α)** cells make **glucagon**, a hormone that tells the liver and muscles to release some of that glycogen they have been storing. (Remember, glycogen is made of strings of glucose molecules.) Glycogen is released into the blood when the level of glucose gets too low (like several hours after a meal). The **beta (β)** cells make **insulin**. Insulin is the hormone that is released when the blood sugar level is too high; it signals the liver and muscles to start pulling glucose out of the blood and start storing it as glycogen. **Delta (δ)** cells make **somatostatin**, a hormone that is made by other places in the body, also, including in the brain (by the hypothalamus, to suppress the pituitary functions). Somatostatin produced by the pancreas affects the digestive organs by telling them to stop making their digestive hormones (insulin, glucagon, gastrin, secretin).

The digestive system has quite a few hormones that send signals to the various organs telling them when to increase their activity. When chyme and stomach acid enter the duodenum, cells lining the duodenum sense this and they begin secreting substances such as **secretin** and **CCK** (never mind what the letter stand for-- it's a very long word!). These hormones go into the bloodstream and eventually (in only a few minutes) end up in the gall bladder and pancreas where they cause these organs to increase production. The stomach actually sends signals to itself, as odd as this might seem. Cells in the stomach produce **gastrin** which goes into the blood and then ends up back in the stomach. The cells in the gastric glands have receptors that sense the presence of gastrin and respond by increasing their production of acid and enzymes.

Processes in the body are never simple! We take eating and digesting for granted and are unaware of the massively complicated chemistry that is occurring inside us. Digestion is actually a lot more complicated than what we have described here. Researchers are still discovering new things about these processes.

You have probably heard about "type 1" and "type 2" diabetes. What's the difference?

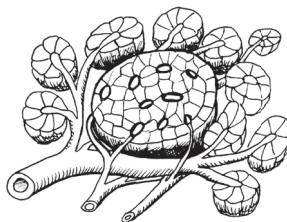
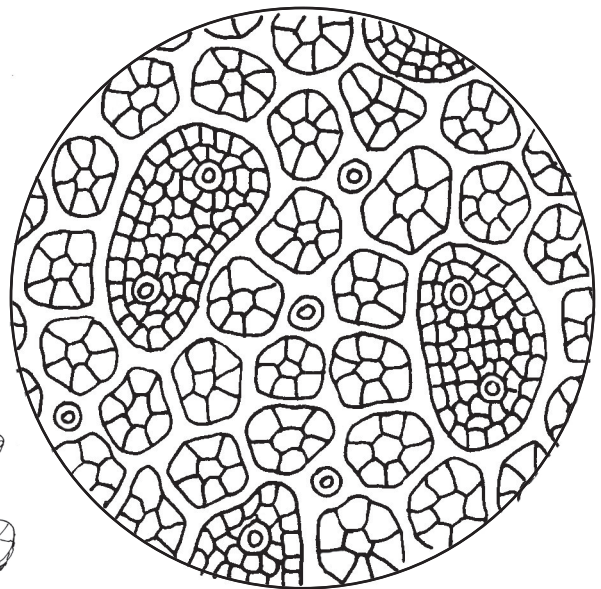

Type 1 diabetes is an autoimmune disease caused by a malfunction of the immune system. Those T cells that are supposed to tag foreign invaders begin tagging body cells by mistake. Macrophages automatically eat anything that is tagged, so if body cells are tagged they get destroyed. In the case of type 1 diabetes, the T cells begin tagging the beta cells inside the islets of Langerhans. (Why? We don't know for sure, but we are suspicious that viruses could be the initiators of many autoimmune conditions.) Once the beta cells are destroyed, the body has no way to make insulin. The level of glucose in the blood will be very high, which will cause all sorts of other problems. The treatment for type 1 diabetes is to take artificial insulin. It is tricky to monitor the level of glucose in the blood and get just the right amount of insulin injected. If you get too much insulin that is also a dangerous situation. People often come down with type 1 diabetes quite suddenly, almost overnight in some cases, and very often the disease begins in childhood.

Type 2 diabetes is something that happens more slowly, often as we get older and possibly as a result of eating too much sugar for many years. It often begins as "insulin resistance," a condition where your cells fail to respond to insulin and don't get all the extra glucose out of your blood. Sometimes type 2 can be managed without taking insulin shots, simply by controlling the diet and getting more exercise. Other times, type 2 may get severe enough that you need to take insulin in order to normalize blood sugar levels.

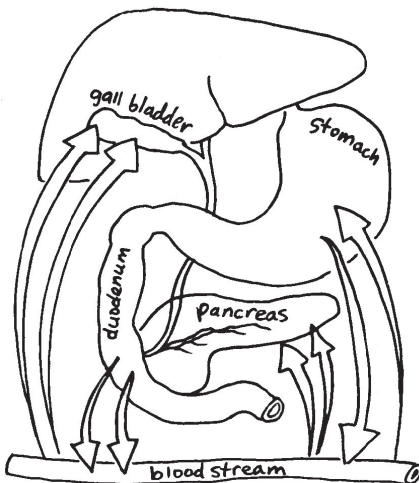
PANCREAS (and enzymes)

71

The pancreas is a "mixed gland" meaning that it performs both **endocrine** and **exocrine** functions. The exocrine products go into the duodenum. The endocrine products go into the blood.



Organs communicate using hormones. When the duodenum detects protein, fats and stomach acid coming into it, its cells start making **secretin** and **CCK**. These hormones go into the blood and eventually reach the pancreas and gall bladder, causing them to increase their output.



EXOCRINE: secreted to OUTSIDE

The exocrine cells are called: _____

Exocrine products of pancreas:

1) _____
(NaHCO_3 that neutralizes stomach acid
(In kitchen we call it: _____))

2) _____ break proteins

ex: _____

ex: _____

ex: _____

These are made as zymogens which are activated by an enzyme in the intestines.

3) _____ breaks apart fats

4) _____ breaks starch into units of maltose (disaccharide)

5) _____ break RNA and DNA

ENDOCRINE: absorbed (by the blood) while INSIDE the gland

The endocrine cells are organized into: _____ of _____

Endocrine products of pancreas:

1) ____ cells make _____
that _____

2) ____ cells make _____
that _____

3) ____ cells make _____
that _____

72: INTESTINES

The intestines are divided into two very distinct regions: the small intestine and the large intestine. The small intestine is subdivided into three regions: the **duodenum** (*du-ODD-den-um, or du-oh-DEE-hum*) the **jejunum** (*jeh-JU-num*) and **ileum** (*ILL-ee-um*).

We've already seen that the duodenum is the part that connects the stomach to the intestines. The pancreas and bile duct are attached here, and the duodenum secretes hormones that help to control the rate of digestion. One of the main functions of the duodenum is to neutralize the acidic chyme coming from the stomach. The pancreatic juice helps with this, but the duodenum also has Brunner's glands that make an alkaline (basic) secretion.

The jejunum gets its name from the Greek word for "fasting." It seems that whenever the ancient Greeks would open a dead body to dissect it, they would always find this part empty, as if the person had not eaten. This mystified them. We now know that the jejunum has the most active peristalsis, and food is moved along through it very quickly. Perhaps in the minutes during and after death, peristalsis pushes the chyme along into the ileum. The jejunum is about 2 meters (6 feet) long, but this is approximate because there is no firm dividing line between the jejunum and the ileum. The pH is somewhere between 7 to 9, so it is slightly alkaline. The diameter of the jejunum is slightly greater than the ileum. The inside has many circular folds called **plicae** (*plee-kay*) **circulares**. The plicae are covered with tiny "fingers" called villi. The villi give the interior a soft, kind of velvety look.

The ileum is about 6-7 meters (18-20 feet) long. The diameter is slightly smaller than the jejunum, the walls are thinner, and peristalsis not quite so fast (possibly because the thinner walls mean less muscle). The pH is still slightly alkaline, between 7 and 8. The ileum is where bile salts are reabsorbed and sent to the liver for recycling. The ileum is also the site for reabsorbing vitamin B12. A notable feature of the ileum, and one of the things that sets it apart from the jejunum is the presence of **Peyer's** (*pie-ers*) **patches**, which are little lumps of lymph tissue. The immune cells in these patches help to fight harmful bacteria.

Both the jejunum and ileum have the four basic layers of tissue: **mucosa, submucosa, muscularis and serosa**. Here around the intestine, the serosa is also called the **visceral peritoneum**. (Visceral means organs.) The visceral peritoneum is called the mesentery when it extends out from the organs. More on that in the next lesson. Note that the mucosa layer has its own very thin layer of smooth muscle called the **muscularis mucosa**. These tiny muscles are moving around all the time, making the villi move and come into contact with the maximum amount of chyme. (Can you imagine the massive tiny network of neurons required to control them?)

The end of the ileum is attached to the beginning of the large intestine (also called the **colon**) at a place called the **cecum** (*see-kum*). The cecum is the part behind the place of attachment, kind of like a dead end. Attached to the cecum is the **appendix**. (The appendix is basically a piece of lymph tissue, and seems to play a role in recovery from intestinal infections.) Right where the ileum attaches to the cecum you find a band of sphincter muscles that control the flow of digested food into the large intestine.

The colon (large intestine) is about 1.5 meters long (5 feet) and is divided into areas using words that describe their location and position: **ascending** (going up), **transverse** (across the top), **descending** (going down), and **sigmoid** (from the Greek letter S: sigma). The thing that looks like a stripe running along the length of the colon is a thin band of muscle. The colon is where water is reabsorbed. The digested food is sloppy when it enters the colon, but when it leaves it should be fairly hard. (But not too hard! Dry feces are difficult to push out, causing a condition called constipation.) When the chyme enters the colon we then refer to it as **stool**.

No actual digestion occurs in the colon. The pH of the colon ranges from 5.5 to 7, so it is slightly acidic. This is a good environment for the helpful bacteria that live there. These bacteria are able to digest some of the fiber (usually plant material) we eat but can't break down. Our bodies don't make the enzymes necessary for breaking down the cell walls around plant cells. The bacteria eat the fiber and then release chemicals we can use, such as vitamin K, some B vitamins, and small fatty acids (which happen to be anti-inflammatory). Eating plenty of fiber ensures that these good bacteria will be healthy. Having lots of "good" bacteria also helps to prevent "bad" bacteria from multiplying.

The very last part of the large intestine serves as a holding area for feces and is called the **rectum**. The ring of muscles at the end of the rectum is called the **anus** (which means "little ring"). When the rectum gets full and begins to stretch, signals are sent to the brain to tell you that you need to use the bathroom. The correct name for solid waste is **feces** (*fee-sees*), and the act of releasing the feces is called defecation.

If we take a microscopic look at the villi, we see five main types of cells.

1) **Enterocytes** take nutrients out of the chyme and put them into the blood or the lymph system. (Words that start with "entero" have something to do with the digestive system.) They produce digestive enzymes such as proteases, lipases, amylase and nucleases. They do the final, final work of digestion, such as chopping those maltose molecules in half, making two glucoses. They also perform a very important function for lipids. They take the tiny bits of fat that the bile emulsified and package them chylomicrons which are then absorbed by tiny lymph vessels called **lacteals**. The chylomicrons will ride in the lymph fluid and eventually get dumped into the blood, along with all the lymph fluid, into a vein right under the collar bone. The enterocytes are the masters of endocytosis and diffusion, constantly taking in nutrients from the lumen, then pushing them out the other side into the space that contains the blood and lymph vessels. (This space is called the lamina propria and is made of loose connective tissue. Many macrophages and lymphocytes (T and B cells) also live here. The edges of the enterocytes have **microvilli**, making a "brush border" that looks fuzzy. The function of both the villi and microvilli is to increase surface area.

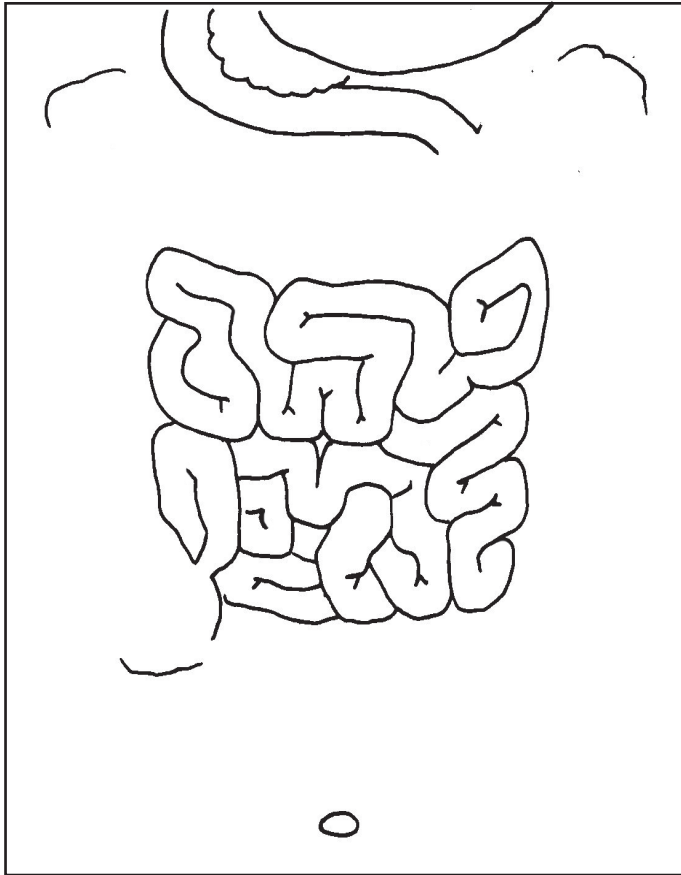
2) **Goblet cells** that make mucus.

3) **Enteroendocrine cells** that make hormones used for communication with other organs.

4) **Paneth cells** that make antibiotic chemicals which are toxic to microbes that might make you sick.

5) **Stem cells** that divide constantly, providing a fresh supply of all these other cells. These other cells only live for about 5 days, so these stem cells are very active. If the stem cells get too active, though, they could form a tumor.

The intestines consist of two distinct regions: the small intestine (divided into **duodenum**, **jejunum**, and **ileum**), and the **large intestine** (also called the **colon**).



What do the jejunum and ileum have in common?

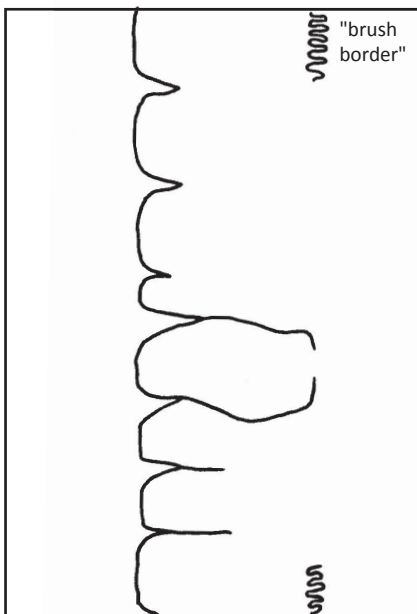
- 1) _____
- 2) _____

Differences between jejunum and ileum:

- | <u>Jejunum</u> | <u>Ileum</u> |
|----------------|--------------|
| 1) _____ | 1) _____ |
| 2) _____ | 2) _____ |
| 3) _____ | 3) _____ |
| 4) _____ | 4) _____ |

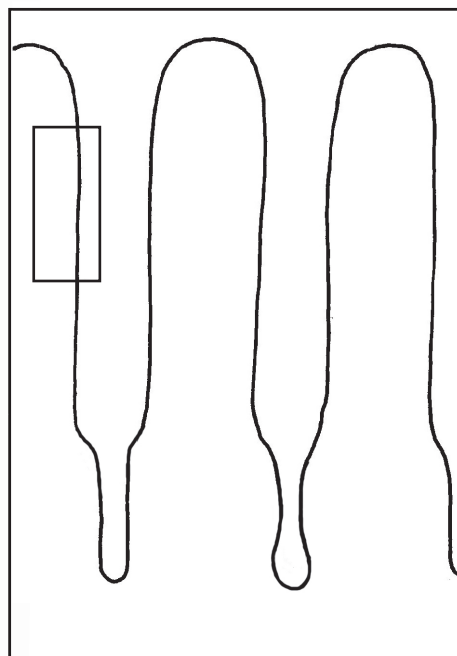
The colon's function is to reabsorb:

MICROVILLI




The enterocytes are the masters of endocytosis and diffusion! Nutrients pass through these cells and out the other side. The cells package triglycerides into chylomicrons that go into the lacteals (lymph vessels). Glucose and amino acids go into the blood capillaries.

VILLI



- | | |
|---------------------------------------|----------------|
| = enterocytes | = goblet cells |
| = enteroendocrine cells | = stem cells |
| = Paneth cells (antibiotic chemicals) | |

PLICAE CIRCULARES



- (1) _____
- a) Epithelium
- b) Lamina Propria (loose connective)
- c) Muscularis Mucosa (very tiny muscles)
- (2) _____
- (3) _____ (circular, long.)
- (4) _____

73: BODY CAVITIES and MESENTERY

We've already mentioned that all the organs in the body are wrapped in "bags" made of thin layers of connective tissue. These bags are often inside of other bags, or even inside of several bags. The largest bags define areas that we call body cavities. There are three main cavities: the thoracic cavity, the abdominal cavity and the pelvic cavity.

The **thoracic cavity** is subdivided into three smaller cavities: the **pleural cavity** (containing the lungs), the **mediastinum** (in the middle), and the **pericardial cavity** (containing the heart). The pleural cavity is easy to understand because it simply contains the lungs. The pericardial cavity contains not only the heart itself, but the large blood vessels that come out of it, such as the aorta. The pericardial cavity is inside of the third cavity, the mediastinum. ("Media" means "middle" and "stinum" can refer to the "sternum," which is the bone that runs down the center of the ribcage.) The mediastinum contains not only the pericardial cavity but also part of the esophagus and trachea, the thymus (remember this organ from module 2 on the immune system?), and quite a few nerves and lymph nodes. The thin layers of connective tissues that surround these cavities are made primarily of collagen and elastin (produced by fibroblast cells) but they also contain some very tiny nerves and blood vessels, as well as cells that make serous fluid. As we've seen in the past few lessons, the diaphragm separates the thoracic cavity from the abdominal cavity.

The **abdominal cavity** contains the stomach, the spleen, the tail of the pancreas, the last half of the duodenum, the small intestines, most of the large intestines, and the mesentery (thin layers of connective tissue that anchor the intestines to the back wall of the abdominal cavity). There would also be many blood vessels and nerves all through the abdominal cavity.

The **pelvic cavity** contains the urinary bladder, the sigmoid colon, the rectum, and the reproductive organs. As with the other cavities there would also be many blood vessels and nerves in this cavity. Oddly enough, the kidneys and most of the pancreas are not in any of these body cavities. They sit behind the abdominal cavity and are called **retroperitoneal** organs. ("Retro" means "behind.")

All three of these cavities, the thoracic, the abdominal and the pelvic can be categorized into one very large area called the **ventral cavity**. ("Ventral" means on the stomach side.) There is also a dorsal cavity, which consists of the cranial cavity, containing the brain, and the spinal cavity, containing the spinal cord. ("Dorsal" means on the back side.)

The mesentery wasn't considered to be an organ until 2012 when anatomists at the University of Limerick, in Ireland, began studying electron microscope images of it. These images allowed them to examine the tissues in great detail. They realized that all the seemingly unconnected sheets of tissue were actually all connected. Since they were all connected and they were all doing basically the same job, this allowed the mesentery tissues to be classified as an organ. The definition of an organ is "a group of tissues that work together to perform a certain function." They felt that the mesentery satisfied this definition and should be added to the list of organs of the body. They presented their research to other scientists and finally everyone agreed to officially declare the mesentery to be an organ. In the past, young students were never taught anything about the mesentery and were thus unaware of its existence. This will change. Now, even elementary students will have to learn the word "mesentery" along with the words "stomach" and "intestines."

What does the word "mesentery" mean? "Meso" means "middle," and "entery" is a variation of "entero" which refers to the digestive system, particularly the intestines. The mesentery isn't all in one place like the stomach or the liver or the pancreas. It is spread throughout the abdominal cavity.

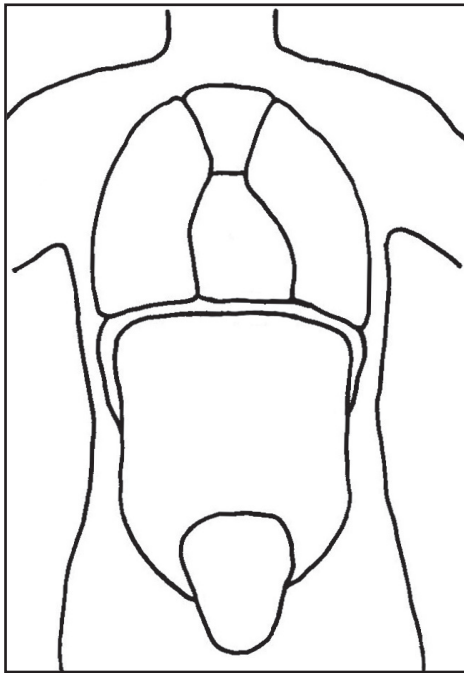
The mesentery looks like very thin sheets of strong connective tissue. They are translucent, meaning clear enough to let light through but not perfectly clear. They have two main jobs. The first is to anchor the intestines to the back wall of the abdominal cavity. Just imagine what would happen if nothing was keeping the intestines in place. All those squiggles and loops of intestine would slide around and get tangled. Gravity would also tend to pull them down and eventually all your guts would sag down to the bottom. Yuck. Good thing the mesentery keeps them in place! The second thing the mesentery does is to provide a surface through which nerves, blood vessels and lymph vessels can run. We'd have the same tangling and sagging problem with all these vessels if they were not anchored in place.

The mesentery is made of two thin layers of serous membrane stuck together. We've already met serous membrane in several places. We saw it around the heart, forming the pericardium, and we also saw it in the lungs, forming the parietal and visceral pleura. Serous membrane is made of a layer of **mesothelium** (a single layer of simple squamous epithelial cells that secrete serous fluid) stuck to a layer of connective tissue (collagen and elastin) made by fibroblast cells. It's the connective tissue layer that contains the blood vessels and nerves.

Serous membranes are called by different names, depending on where they are located. When the serous membranes line the walls of the body cavities they are called **parietal peritoneum**. (Remember, "parietal" means "wall.") When the membranes wrap around organs they are called **visceral peritoneum**. ("Visceral" means "organs.") When two membranes are stuck together to form a sheet, they are called **mesentery**. Serous membrane around the lungs is called **pleura**, and serous membrane around the heart is called **pericardium**.

There are names for various parts of the mesentery. The part that holds the colon in place is called the **mesocolon**. There is a sheet of tissue between the liver and stomach that is called the **lesser omentum**. There is a large sheet of tissue called the **greater omentum** that acts like an apron, covering the front of the small intestines.

BODY CAVITIES are large sections of the body that are enclosed by membranes.



There are 3 main body cavities:

- 1) _____
 a) _____ (_____)

 b) _____ (_____)

 (is inside mediastinum)

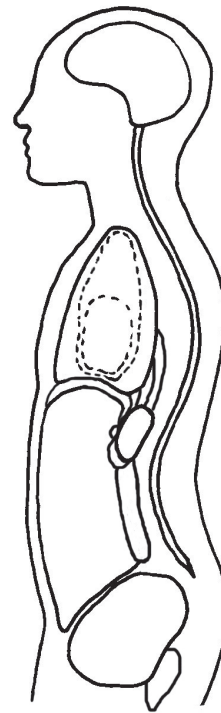
 c) _____

 (superior part shown)

 (includes superior vena cava, aortic arch, thymus, part of esophagus, part of trachea)
- 2) _____

 (contains stomach, spleen, liver, gall bladder, part of pancreas, all of small intestines, transverse colon)
- 3) _____

 (contains urinary bladder, reproductive organs such as uterus, and sigmoid colon)



Just FYI, there are 2 other "official" body cavities:

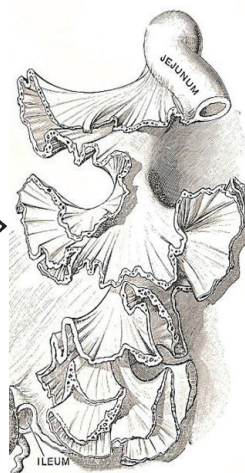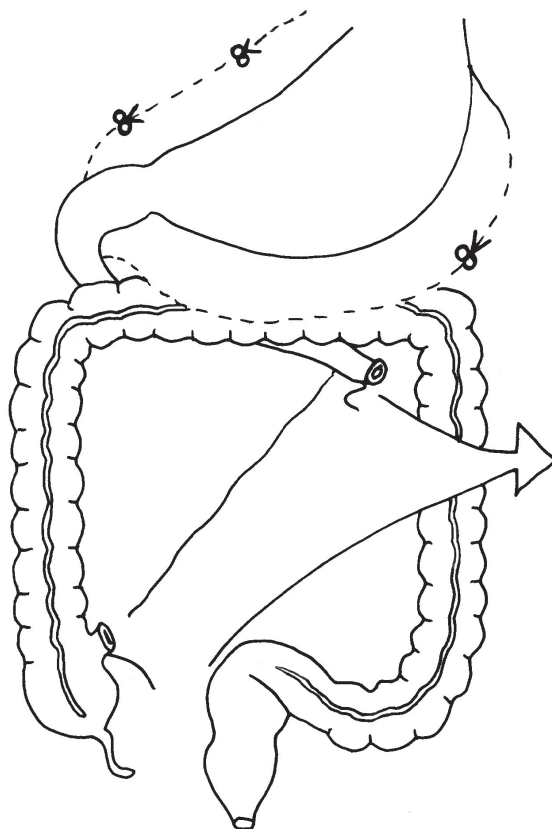
- CRANIAL
- SPINAL

A few organs lie outside of the cavities.

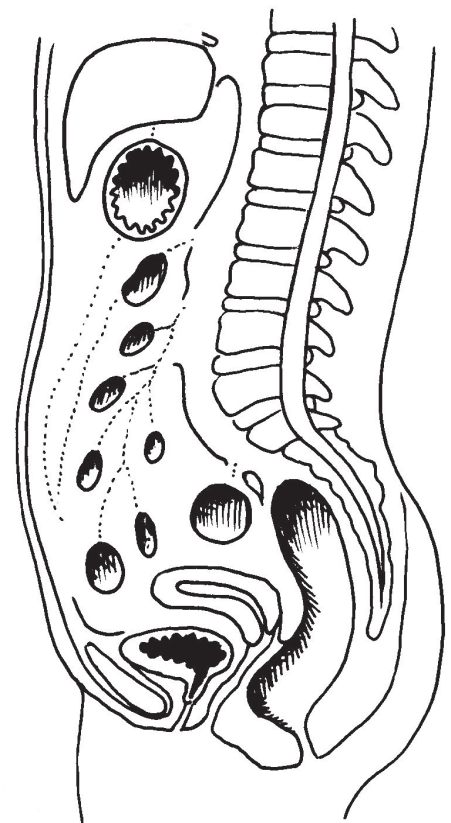
They are called **retroperitoneal** ("retro" means "behind").

- Aorta (descending)
- Vena cava (inferior)
- Kidneys
- Part of duodenum
- Part of pancreas
- Ascending colon
- Descending colon
- Rectum

THE MESENTERY is a very thin membrane that holds all the organs in place. The mesentery also provides a surface for nerves, blood vessels, and lymph vessels. Mesentery is made of serous membrane (which is made of a layer of simple squamous epithelial cells stuck to a layer of connective tissue).



This is how the mesentery would look if you cut off all the intestines. (The wavy shape might remind you of some plant leaves such as kale or parsley.)



NOTE: Small intestines have been removed in this diagram.

74: KIDNEYS and BLADDER

The kidneys and bladder (and their various tubing) make the urinary system. The goal of this system is to gather what is called "metabolic wastes" and excrete them in a liquid we call urine. Solid wastes go out in the feces. The type of wastes the kidney deals with are tiny molecules made of less than 20 atoms. The waste molecule called **urea** is what gives urine its name. Urea is made from **ammonia**, NH_3 , a waste that is formed when amino acids are torn apart. Carbohydrates and fats don't have any nitrogen in them, so they can be broken apart and burned in the Krebs cycle. When amino acids are broken apart, one of the broken pieces is a molecule of ammonia, NH_3 . Ammonia is toxic to the body, so the body has to have an immediate way to deal with it. The liver takes two NH_3 's and one CO_2 and combines them to make $\text{CO}(\text{NH}_2)_2$, or urea. Urea is still a waste but it is not that toxic and can safely wait a while to be expelled. Another metabolic waste that helps to give urine its name is **uric acid**. Uric acid is formed as a by-product of the breakdown of nucleic acids (rungs of DNA and RNA). A third type of nitrogenous waste is **creatinine**, which is a by-product of the breakdown of creatine, a molecule in the muscles that acts a bit like ATP, with phosphates that supply energy. (We'll learn more about that in the muscle drawing.) Urine might also contain other small waste molecules containing phosphates or sulfates, as well as various small molecules from food or medicines.

The kidneys are located behind the peritoneal membrane, as we saw in the last drawing. Blood is supplied to the kidneys through the **renal artery** and the **renal vein**. (Anything starting with "renal" will be related to the kidneys.) There are little organs sitting on top of the kidneys called the **adrenal glands**. We will learn more about them in the lesson on the endocrine system. The tubes that come out of the kidneys and go down into the bladder are called the **ureters** (*YOUR-eh-ters*). These tubes are lined with small muscles that use peristalsis to push the urine down into the bladder. If gravity was the only force that pulled urine down the tubes, you'd have problems at night when you are lying flat. Urine would collect inside the kidneys and cause major problems. Speaking of night and sleeping, you also get help from your pituitary gland, which secretes a substance called ADH (anti-diuretic hormone) while you are asleep. ADH tells the kidneys to reabsorb as much water as they can, making less urine. Sometimes you still have to get up in the middle of the night to go, but you go less than you would during the day.

The bladder is a waterproof, stretchy bag that collects the urine and holds it there until you get a chance to get rid of it. We saw bladder epithelial tissue in lesson 31. The cells that line the bladder are of a special type that isn't found anywhere else. As the bladder fills and these cells stretch, they send signals along nerves to the brain. The result is that feeling that your bladder is full and you have to find a bathroom. There are sphincter cells at the top and bottom of the **urethra** (*you-REETH-ra*), the tube that leads to the outside. The top sphincter is made of smooth muscle and is involuntary. The bottom sphincter is made of skeletal muscle and is under voluntary control; it is this bottom sphincter muscle that you relax when you urinate. In males, this lower sphincter is not right at the opening, as it is in females. In males the sphincter is closer to the bladder, just under the prostate gland that sits below the bladder. In females, the urethra is only about 4 cm long, whereas in males it is about 20 cm long. In females, the urethra is completely separate from reproductive parts, but in males the urethra is part of both the urinary and reproductive systems. More on this in a later lesson.

There are also tiny sphincters where the ureter tubes attach to the top of the bladder. These muscles open anywhere from 1 to 5 times per minutes, allowing a little spurt of urine to enter the bladder each time. When our systems are healthy and working as they should, we are completely unaware of these little spurts going on all the time.

If we look at a cross section of a kidney, we see it divided into a number of distinct areas called **pyramids**. The top portion of these pyramids belongs to the outer layer, called the **cortex**. The bottom of the pyramids belongs to the central core called the **medulla**. There are tubes coming out of the pyramids, feeding into a large tube which will become the ureter.

If we take a close up look at a pyramid, we see that it is made of thousands of individual units called **nephrons**. The nephron is the functional unit of the kidney. Each nephron has a capillary bed around it, called the **peritubular capillary network**. If we follow the incoming arteriole, we see that it goes into a tiny sphere called a **Bowman's capsule**. Inside this capsule, the arteriole branches into very tiny capillaries, creating a tangle called the **glomerulus** (*glom-AIR-u-lus*). The narrowing of the diameter of these capillaries causes the pressure inside of them to go up. (When you want to create more pressure in a garden hose, you twist the nozzle so that it becomes smaller.) This pressure in the glomerulus causes tiny molecules to be squeezed out-- molecules such as water, salts, glucose, amino acids and urea. Large things like blood cells, platelets, globulins, and clotting proteins, etc., are too large to escape. The filtration process is aided by special cells called **podocytes**, that have many feet ("podo" means "feet") that create tiny cracks. (Think of standing in muddy water and having fresh, clean water squeezed up from between your toes.)

This liquid "filtrate" then goes into the walls of the capsule, and then into a long twisted tube called a **convoluted tubule**. The walls of the tube are made of cuboidal cells with many microvilli that increase surface area. Some of the water and nutrients that were taken out are now reabsorbed by these microvilli and then transferred back into nearby capillaries. The cuboidal cells lining the tubes have special carrier proteins that recognize molecules that the body should recycle. The number of carriers for each type of molecule (nutrients, salts, vitamins, etc.) corresponds to how much should actually be in the blood. There are a lot of carriers for some things and less for others. For example, there are lots of carriers for glucose, because all of the glucose should be reabsorbed at this point. (In the case of diabetes, there is so much glucose in the blood that there are not enough carriers to pick it all up and some glucose goes right through the tubes and ends up going into the urine. Testing for glucose in the urine is a key test for diabetes.) The fact that there are only a certain number of carriers for each type of nutrient molecule is what keeps our body from being overwhelmed with too much of something. We can eat out-of-balance meals and our kidneys will strain out the excess amounts of most things. If you eat an entire bag of pretzels or chips, all that excess salt will be filtered out and go into the urine. If you take a vitamin tablet and your body doesn't need all those vitamins, the excess can be filtered out at this point.

The tube twists around, then dips down to create a long U-shaped loop, called the **loop of Henle**. The first part of the loop, the descending portion, is very narrow and is lined with leaky epithelial cells that allow water to seep out. The ascending portion is narrow at first, then gets larger. This upward part of the loop is watertight so water can't leak out here. In this part of the loop, Na^+ ions are actively pumped out and go back into the nearby capillaries. (We saw sodium pumps in the nervous tissue lesson. You can find them in many places in the body.) When Na^+ ions leave, Cl^- (chlorine) ions will naturally follow them because the ions are attracted to each other, being +1 and -1. This puts a lot of NaCl (salt) outside of the tubes, and creates an imbalance in water concentration. The process of osmosis will cause water to flow to areas that have a lesser concentration of water (and a higher concentration of solutes like NaCl). In this case, osmosis will make water flow out of the tubes and back into the blood.

NOTE: The water and salts can hang out for a while in the medulla tissue. They don't always go immediately back into the capillaries. Some diagrams have arrows pointing out into the tissue, not into capillaries. This can be confusing. The answer is that the water does go back into the capillaries but sometimes not immediately.

The very last part of the convoluted tubule (the distal part) has cells that can actively transport certain molecules out of the blood and into the urine. For example, molecules of penicillin and creatinine are pulled out in this way. This last part of the tubule is the last chance the nephron has to pull things out of the blood or to excrete more water.

So what is left in the end? What is urine made of? Mostly water, with small amounts of salts, urea, uric acid, ammonium and creatinine. (More about creatine and creatinine in a future lesson.)

About 99 percent of the salt in our blood is filtered out by the glomerulus, then returned to the blood at various points in the nephron. 67 percent is returned right away in the proximal (near) part of the convoluted tubule. Another 25 percent is pumped out in the upward (ascending) part of the loop of Henle. The last few percent is reabsorbed in the last part (the distal part) of the tubule, before it feeds into the ureter. The salt balance in the blood is very important to maintaining the correct volume of blood. Blood volume is an important factor in blood pressure. Too much salt in the blood will cause water to want to come into the blood vessels to equalize the concentration of water inside and outside the vessels. This is why doctors might tell someone with high blood pressure to decrease the amount of salt in their diet. Salt causes an increase in blood pressure. The kidneys try their best to maintain balance, but sometimes systems struggle to keep up and we can ease the situation by adjusting our eating habits.

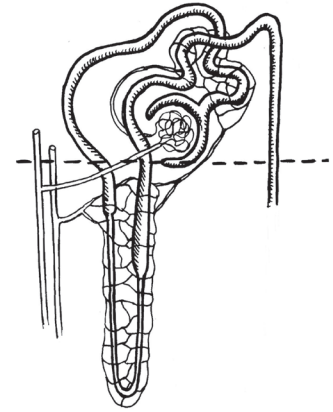

There is a special place in the nephron that is devoted to monitoring blood pressure—right where the arteriole comes into the Bowman's capsule. The incoming (afferent) arteriole touches (and is actually connected to) the far (distal) portion of the convoluted tubules. After the tubule dips down and forms that loop of Henle, it goes up and touches the incoming arteriole. This touch point has a special name that looks very complicated: the **juxtaglomerular apparatus**. ("Juxta" means "crossing point" and "glomerular" refers to that tangle of capillaries we call the glomerulus. The word "apparatus" seems a bit too fancy for a simple-looking touch point, but oh well.) The cells of this touch point can sense when there is not enough pressure in the glomerulus. Not enough pressure means that things are not being filtered out. So the cells of this "apparatus" begin making an enzyme called **renin**. The renin turns a molecule called angiotensinogen into its active form, angiotensin. ("Angio" means something related to blood vessels. "Tensin" is related to the word "tension" meaning "tight.") Angiotensin causes blood vessels to tighten. Think about that hose again. Making the diameter of a hose or tube smaller will cause the pressure inside to increase. So angiotensin will increase blood pressure. Angiotensin also acts as a messenger molecule to the adrenal glands that sit on top of the kidneys. It tells the adrenals to start producing **aldosterone** (*al-DOST-er-one*). Aldosterone is a hormone that promotes the reabsorption of Na^+ ions. When salt is reabsorbed into the blood, water also flows in and blood volume and blood pressure increase. But what if blood pressure gets too high? The sensor mechanism for this is located in the aorta. As blood volume increases, the aorta will experience more stretching. There is a tiny sensor spot in the aorta that senses this stretching and begins to secrete ANH (atrial natriuretic hormone), a hormone that stops the secretion of renin and aldosterone.

Just in case you are still interested in knowing more, a recent research project (2009-2011) was done using men who were training to be astronauts to Mars. While sealed into their spacesuits for many days, researchers were able to control exactly the amount of salt the men took in, and to measure exactly how much salt came out in the urine. They fed the men a diet very high in salt for a while and watched what happened. The results were not what they expected. Extra salt only came out in urine something like once a week or once a month. It appeared that the rest of the time, the kidneys were finding other ways to manage the extra salt. The kidneys got better at conserving water. The men did not get extra thirsty or need to drink extra water, which was quite the opposite of what was expected. The urinary system is "smart" and can adapt to unusual situations.

Another function of the kidneys is to help keep the pH of the blood at a constant 7.4. Part of pH balance occurs in the lungs, as the balance of H^+ (hydrogen) ions and HCO_3^- (bicarbonate) ions is constantly changing. If the blood becomes too acidic (too many H^+ ions in it) the breathing center in the medulla oblongata will tell you to start breathing faster in order to rid the body of hydrogen ions. (The hydrogen ions will end up as H's in water molecules expelled along with CO_2 when you exhale.) The kidneys can also reabsorb or excrete H^+ and HCO_3^- ions. The kidneys have a trick that the lungs don't have. They can also use ammonia, NH_3 , as a way to remove H^+ ions from the blood. NH_3 comes into the kidneys as the waste product made by cells that tore apart amino acids. The NH_3 molecule can take on an extra hydrogen and become NH_4^+ (ammonium). This ammonium can be sent out with the urine. This ammonium is what makes the nose-tingling smell found in diaper pails and cat litter boxes.

Lastly, the kidneys do something completely unrelated to all the water and salt balance stuff. They monitor the level of oxygen in the blood and secrete the appropriate amount of **erythropoietin**. (Remember, "erythro" means "red" and "poie" means "to make.") Erythropoietin (ee-RITH-ro-po-EE-tin) tells the hematopoietic stem cells in the bone marrow to make more red blood cells. This exact place this happens is a little hard to determine, but it seems to be mostly in cells of the cortex that are close to the capillaries that surround the tops of the tubules.

The functional unit of the kidney is the **NEPHRON**

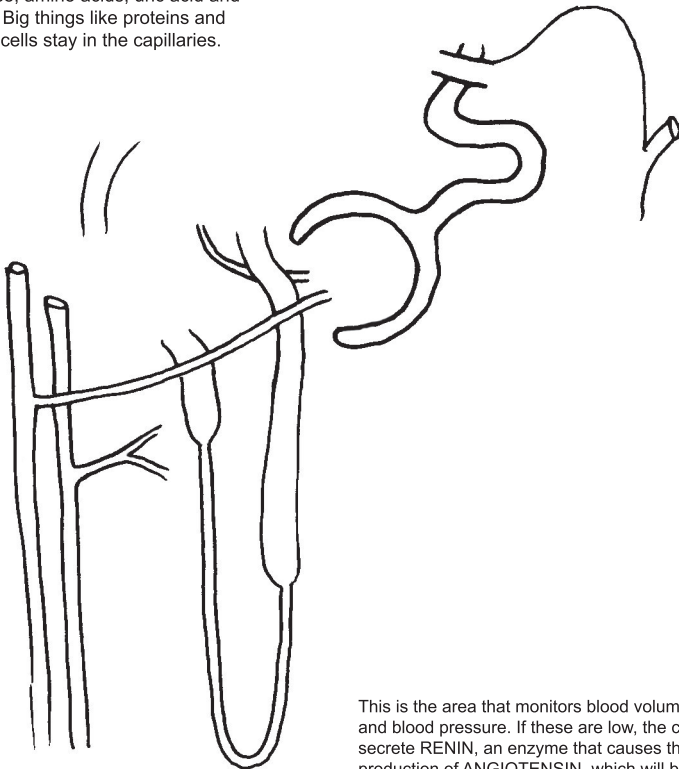


LENGTH OF URETHRA

WALL OF BLADDER

In the **GLOMERULUS**, the blood is under pressure. Very tiny molecules are pushed out: water, salts, ions, glucose, amino acids, uric acid and urea. Big things like proteins and blood cells stay in the capillaries.

In the **CONVOLUTED TUBULES**, water is reabsorbed and goes back into capillaries, but only a certain number of small molecules go back.



This is the area that monitors blood volume and blood pressure. If these are low, the cells secrete **RENIN**, an enzyme that causes the production of **ANGIOTENSIN**. which will both constrict blood vessels and tell the adrenal cortex to produce **ALDOSTERONE**, which makes more sodium go into the blood.

SUMMARY OF KIDNEY FUNCTIONS:

- 1) _____
Nitrogenous wastes come from the breakdown of amino acids, which have a nitrogen atom. (The liver turns ammonia into urea.)
- 2) _____
This is achieved through a balance of water and salt in the blood. The more salt in the blood, the more water goes into the blood, and that means greater blood volume and greater pressure. To increase blood pressure, the kidneys secrete renin, which activates angiotensin, which tells the adrenals to make aldosterone which causes more sodium to go into the blood.
- 3) _____
The kidneys can excrete or reabsorb both H^+ ions (which make things acidic) and HCO_3^- ions (alkaline).
- 4) _____
If the kidneys sense that there is less oxygen in the blood, they will begin to produce more erythropoietin, which tells the hematopoietic stem cells to make more red blood cells.
- 5) _____
Vitamin D from the diet must be converted to a more active form that the digestive system can use to absorb calcium ions.

NOTE: The pituitary gland (in the brain) secretes a chemical called **ADH** (anti-diuretic hormone) at night, which causes more water to be reabsorbed, making less urine.

75: BONES (as organs)

We won't be learning the names of bones in this lesson. This lesson is just about how a bone functions as an organ. Like all organs, a bone is a group of tissues that work together for a common goal. As with the other organs, we will see many types of tissue in bones, but connective tissue will predominate. The goals of a bone are:

- 1) be a framework for muscles (and/or a protector of organs)
- 2) produce blood cells
- 3) store minerals, especially calcium

Our drawing shows the humerus bone, though a middle section had to be taken out for it to fit on the page and still be wide enough to show the internal structure. It is one of the "long bones" in the body, connecting the shoulder to the elbow. All long bones have a layer of **hyaline cartilage** on the end. You may have seen this shiny white layer on the end of a chicken bone. The knobby end of the bone is called the **epiphysis** (*ee-PIFF-eh-sis*). The long, straight shaft is called the **diaphysis** (*die-AFF-eh-sis*).

Inside the epiphysis is **spongy bone**, also called **cancellous bone** or **trabecular bone**. The spongy bone is filled with red marrow, so it looks red. The red comes from the red blood cells that are being produced. The red marrow is where the hematopoietic stem cells live, so the red marrow also produces platelets and all types of white cells. (See lesson 36 for review of hematopoietic stem cells.)

There is another layer of cartilage in long bones, located between the epiphysis and the diaphysis. This layer is called the **epiphyseal plate** (*ep-i-FIZZ-ee-al*), or the growth plate. While children are growing, this plate is the site of bone lengthening. (A disorder called achondroplasia is caused by a malfunction in this layer of cartilage. The result is very short arms and legs, a form of dwarfism.) During puberty, levels of the hormone estrogen rise in both males and females, and this is what tells the chondrocytes in this plate to stop reproducing. Thus, bones stop growing. A very thin plate remains, even in adults, although it no longer causes bone growth.

Inside the shaft (diaphysis) there is a **medullary cavity** filled with yellow marrow. In children, this cavity actually still has red marrow in it, but as they grow older the red marrow will be replaced by yellow marrow. Yellow marrow is yellow because of the great number of adipose (fat) cells in it. The yellow color of the fat cells comes from natural food colors such as carotene which makes carrots orange. Fat cells can hold on to carotene.

Bones have tiny holes at various points that allow blood vessels to enter. These holes are called **nutrient foramina**. Arteries and veins bring in nutrients and take away wastes as well as picking up all those new blood cells that are being created.

Bones are covered with a thin layer of serosa-type membrane called **periosteum**. ("Peri" means "around," and "osteum" means "bone.") The periosteum continues off the end of the bone and will help to connect the bone to other connective tissue such as tendons and ligaments.

The bone around the medullary cavity (the bone that makes the shaft) is called **compact bone**. Compact bone is made of a network of collagen fibers that is filled with minerals such as calcium and phosphorus. We can think of compact bone as being a bit like concrete that is reinforced with re-bar. The re-bar rods are like the collagen fibers and the concrete is like the minerals. Cells called **osteoblasts** make the compact bone by secreting collagen and then filling it with minerals (mostly calcium and phosphorus but some magnesium and possibly other ions as well). Osteoblasts are made from stem cells in the outer layer of the bone, right under the periosteum. (You can review information about osteoblasts in lesson 35.)

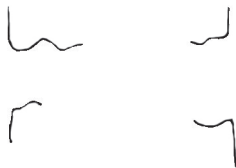
If we look at a close-up view of compact bone, we see that it is made of osteons. (See lesson 35 for review of osteons.) Blood vessels go into the bone from outside, and create a network of vessels inside the bone, mainly going through the central canals. The periosteum around the outside has two layers. The outer layer is tough and fibrous. The inner layer has many cells in it, including stem cells, fibroblasts that make collagen, osteoblasts and osteoclasts.

Bones are constantly being remodeled. When the calcium level in the blood drops too low, a signal is given to cells called **osteoclasts** to start dissolving bone and releasing the calcium ions into the blood. Calcium is important for many body processes. Hopefully, you remember that the clotting cascade uses calcium, and that it plays a vital role in muscle contraction. Osteoclasts are a very different type of cell from osteoblasts. The osteoclasts do not come from stem cells in the outer bone like osteoblasts do. The osteoclasts might actually be a type of macrophage. (Research is still being done on this.) The osteoclasts secrete H^+ ions (protons) into the bone to dissolve the minerals. They also secrete an enzyme called **collagenase** to dissolve the collagen fibers. When the osteoclasts have been going a while, they will start to produce chemicals that will help to call osteoblasts over to make repairs. Osteoblasts come along and fill in the holes that the osteoclasts made. So you have this continual, ongoing process of remodeling, in order to keep the level of calcium in your blood constant.

BONES (as organs)

75

You will want to go back and review drawings 35 and 36 before doing this drawing.



BONE REMODELING (Blasts VS Clasts)

- Osteons are constantly being torn apart and rebuilt.
- When calcium levels in the blood get too low, **OSTEOCLASTS** dissolve bone to release calcium ions (Ca^{2+}).
- When calcium levels in the blood are high, the **OSTEOBLASTS** put calcium back into bone by building up the osteons.

CLAST = tear down

BLAST = build up

Osteoclast is secreting acid (H^+ ions) to dissolve the mineral content. It will secrete an enzyme called **collagenase** to dissolve collagen.

Osteoblasts might be a type of macrophage.

76: THE SKELETAL SYSTEM

Finally, we get to name the bones! You probably already know some of these names. We are just going to label the major bones of the body, not every bone. If you want to know the names of smaller bones (or the names of the parts of the bones, as every lump and bump has a name) you can easily search the Internet and find them.

Scientists think of the skeleton as having two parts. The **axial** (*AX-ee-el*) skeleton consists of the skull, the spine and the ribcage. The **appendicular** (*ap-en-DIK-u-lar*) skeleton refers to the arms and legs. ("Appendage" means something that sticks off something else.)

The arms hang from the "pectoral girdle," which is a framework made by the **clavicle** (collarbone) and the **scapula** (shoulder blade). Right where the clavicle and the scapula meet at the shoulder, there is a smooth, cup-shaped depression that forms a "socket" for the smooth head of the **humerus** (upper arm bone). This type of joint is called a ball-and-socket joint and we'll look at it again in the next lesson. Below the humerus we find two bones, the **ulna** and the **radius**. Both of these bones are connected to the wrist, which is made of a clump of 8 bones called **carpals**. (Connective tissue keeps all these lumpy bones in place, of course.) The longest bones of the hand, found in the palm and in the thickest part of your thumb, are called the **metacarpals**. The bones of the fingers are called **phalanges** (*fal-AN-geez*). The phalanges that are closer to the metacarpals are called the **proximal** phalanges. ("Proxi" means "close.") The phalanges at the tips are called the **distal** phalanges. ("Distal" means "distant.") The distal phalanges are the ones that are the farthest away from the wrist.) The ones in the middle are called the middle phalanges. The thumb does not have a middle phalange.

The legs are hung from the "pelvic girdle," which is made of the **coxal bones** and the sacrum. The wide back part of the coxal bone is called the **ilium** (not to be confused with the ileum). The ilium is the bone that we feel when we put our hands to our hips. The frontal part of the coxal bone is called the **pubis**. The bottom of the coxal bone is called the **ischium** (*ISS-key-um*) and this is the part of the bone we sit on. The two coxal bones are joined in the back by the sacrum, and in the front by a piece of fibrocartilage called the **pubic symphysis** (*SIM-fuh-sis*).

The rounded top of the **femur** fits perfectly into a bowl-shaped depression in the **coxal bone**. This joint is a ball-and-socket joint, just like the shoulder joint. The bottom of the femur is attached (at the knee) to two smaller bones called the **tibia** and the **fibula**. The bone on the front of the knee (the knee cap) is called the **patella**.

Right under the tibia and fibula you find the 7 tarsal bones. The top tarsal bone is called the **talus** (*TAY-lus*). The tarsal that forms the heel is called the **calcaneus** (*cal-KANE-ee-us*). The foot has long bones similar to the metacarpals in the hand. These long foot bones are called the **metatarsals**. The bones of the toes are called the **phalanges**, just like the finger bones.

The names of the bones of the skull are very similar to the names of the lobes of the brains. For example, the **frontal** bone covers the frontal lobe. Thus, we also have the **temporal** bone, the **parietal** bone and the **occipital** bone. You may already know that the correct name for the jaw bone is the **mandible**. We met the **sphenoid** bone and the **ethmoid** bone in lesson 60. (The sphenoid is that butterfly shaped bone on the bottom of the skull. The ethmoid is in the sinuses.) The bone that holds the top row of teeth is the **maxilla**. The **nasal** bone connects the two maxilla bones and forms the top part of the nose. The **zygomatic** bone is the framework for your cheek. The top part of this bone, under the outside of the eye, is called the **zygomatic arch**.

The spine is made of 33 vertebrae. The top 7 vertebrae are called the **cervical vertebrae** and they form the neck. The first cervical vertebra, right under the skull, is the **atlas**. (In Greek mythology, Atlas was the god who held the earth (or the celestial sphere) on his shoulders. If you imagine your skull to be a globe, then your atlas is Atlas.) Your atlas isn't like any of the other vertebrae. It has a special shape that fits with the skull on top and with the second cervical vertebra below it, called the **axis**. The atlas is the bone that allows you to nod your head up and down and tip it side to side, and the axis allows you to look left and right. Working together, these two bones allow you to move your head in any direction. (As an important side note, if these two bones get knocked out of alignment, they can pinch the nerves coming out of your brain stem and cause quite a variety of health issues, such as headaches, digestive disturbances, neurological problems with arms or legs, brain problems like depression or "brain fog," and even (in a few documented cases) nervous system diseases such as MS. Most chiropractors don't deal with these two vertebrae. Special chiropractors, called upper cervical chiropractors, make precise measurements of the misalignment and tap the bones back into place. (If you've had head or neck injury get your atlas checked and spare yourself future problems.) The rest of the cervical vertebrae are simply known by their numbers: C3, C4, C5, C6, and C7.

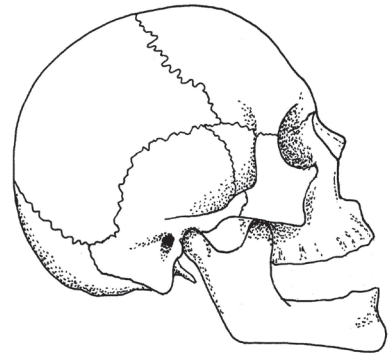
The next 12 vertebrae are called the **thoracic vertebrae**. These are the vertebrae that are attached to your ribs. You have twelve pairs of ribs and ten of these pairs are fastened to the vertebrae in the back and the sternum bone in the front. The two bottom pairs of ribs, number 11 and number 12, are called "floating ribs" because they don't attach to the sternum, only to the spinal vertebrae in the back. None of the thoracic vertebrae have special names. They are called T1, T2, T3, etc.

Below the 12 thoracic vertebrae are 5 **lumbar vertebrae**. The nerves that come out of the lumbar go into the organs in the lower part of the torso, such as bladder and rectum, and down into the legs. Numbers are used for the lumbar: L1, L2, L3, etc.

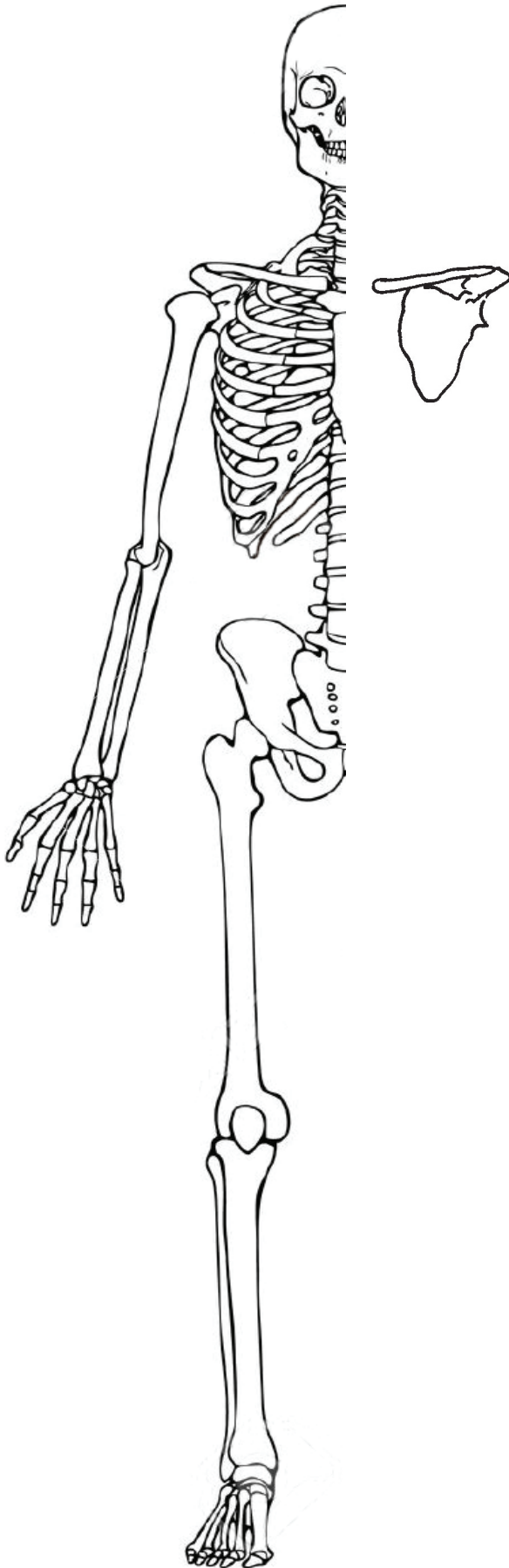
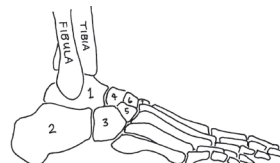
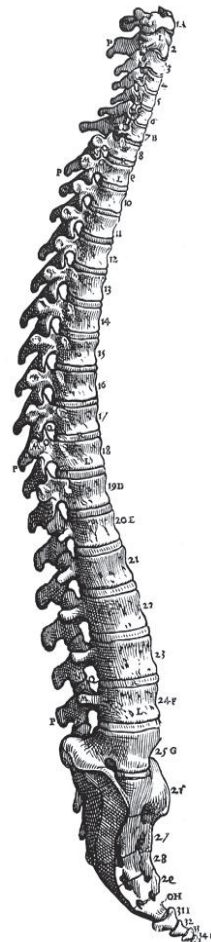
Between all the vertebrae you find thick pads made of dense fibrocartilage. This padding allows the vertebrae to move around a bit, but hopefully not slip out of place too much.

Below L5 we have the **sacrum** (*SAY-crum*). The sacrum looks like one piece but is actually 5 vertebrae that are fused together. The sacrum sits between the two coxal bones that form the hips. The last tiny bit of the spine is called the **coccyx** (*KOK-siks*) and it appears to be 4 tiny vertebrae fused together. The common name for the coccyx is the "tail bone." The word coccyx comes from the Greek word for the cuckoo. The namers of this bone thought that the coccyx resembled the beak of this bird.

BONES of the SKULL:



BONES of the SPINE:



This drawing is by Andreas Vesalius, first published in 1543. His book, "De Humani Corporis Fabrica" is considered to be the first modern anatomy textbook.

77: JOINTS

There are three types of joints. Joints that are freely movable (like the knees, elbows, wrists, etc.) are called **synovial joints**. Joints that are very firm and only slightly movable are called **cartilaginous**. Joints that don't move at all are called **fibrous**. Let's begin with the fixed, immobile joints and end with the movable ones we are most familiar with.

Fibrous joints are places where two bones come together and are firmly attached, as if they are glued together. The **sutures** in the skull are the most well-known fibrous joints. The cranium bones were once separate, when the body was still in its embryonic state. The separations between the bones made it easier for the head to go through the birth canal. After birth, the gaps begin to narrow, and after a few years the cranium is basically one solid piece. The place at the bottom of a tooth where it is held into its socket also counts as a fibrous joint. The pairs of bones in the arms and legs (ulna and radius, and tibia and fibula) are connected at both ends by a fibrous joint.

Cartilaginous joints are not completely fixed, but are only slightly movable. These joints are made entirely of shiny, white hyaline cartilage, which is why they are called cartilaginous. The vertebrae are connected by this type of joint. There are solid discs (intervertebral discs) of hyaline cartilage between all the vertebrae. These discs allow the vertebrae to move just enough so that you can twist your back to the left and right and bend over, but the joints are stiff enough to give the back the strength it needs to be a framework for the rest of the body. (If these discs slip out of place, the result can be very painful.)

The pubic symphysis, which we met in the last lesson, is also a cartilaginous joint. The symphysis joins the two coxal bones but allows just a tiny bit of flexibility when necessary. The costal cartilage that connects the ribs to the sternum also counts as a cartilaginous joint, though we don't tend to think of it as a joint.

The **synovial joints** are the ones that immediately come to mind when we think about joints: the knee, hip, elbow, wrist, shoulder, ankle. Synovial joints have some special characteristics that the first two categories don't have. The bones of the synovial joints are held together by ligaments. **Ligaments** are like biological steel cables or ropes, and are incredibly strong for their size. Since they are made of collagen, they easily connect to the collagen framework found in bones. The bones also have tendons connected to them. **Tendons** connect bone to muscle. Remember that muscles are surrounded by bags of connective tissue, so it is this connective tissue that connects to the bone.

Between the bones of the synovial joint there is a space called the **synovial capsule**. The capsule is made of a thin membrane very similar to serous membrane. Some of the cells in the membrane secrete a fluid called **synovial fluid**, similar to serous fluid. This synovial capsule acts as a shock absorber and keeps the bones from rubbing against each other. In the large synovial joints such as the knee and hip, there are additional pads and cushions such as bursae (fluid filled sacs) and pads of fat.

There are six types of synovial joints:

Hinge: elbow, knee

Ball and socket: shoulder, hip

Pivot: atlas/axis in neck, radius at elbow

Saddle: base of thumb

Plane (or "gliding"): between carpals/tarsals, between sternum and clavicle

Ellipsoidal (or "condyloid"): between metacarpals and phalanges

NOTE: Sometimes intervertebral joints (between the vertebrae) get classified as plane joints. The ellipsoid category can also be a bit loose, with some disagreement about which joints belong in that category.

Let's look at a cross section of the knee. The knee is where the bottom of the femur is joined to the top of both the tibia and fibula. The ends of the bones are covered with slippery, white hyaline cartilage. The slippery nature of the cartilage helps the joint to be almost friction-free. Friction is also reduced by slippery pads called **menisci** (singular: **meniscus** [*meh-NISS-cuss*]), and by about a dozen fluid-filled capsules in and around the joint, called **bursae** (singular: **bursa**). The bursae (*burs-ay*, or *bur-see*) are filled with fluid, just like the synovial capsules. The bursae help ligaments and tendons to slide past each other easily as you bend your knee. Inflammation of the bursae is fairly common, and is called **bursitis**. The cruciate (*CRU-she-ate*) ligaments get their name from the fact that they cross each other. ("Cruc" or "crux" means "cross") Cruciate injuries are common in sports, especially football.

The **patella** (knee cap) is held in place from above by the **quadriceps tendon** and from below by the **patellar ligament**. The patella not only protects the knee joint, it also acts as a fulcrum if you think of the leg bones as levers. The patella pushes the tendons out from the knee a bit, acting to increase leverage, giving mechanical advantage to your leg muscles. (Meaning you get more action for your effort.)

The hip is obviously a ball and socket joint. The head of the femur is the ball, and a concave surface on the pelvic bone makes the socket. ("Concave" means that it curves in, like the entrance to a cave. Convex is a curve that protrudes outward. The ball is the convex surface.) In this simple hip diagram, we see ligaments connecting the bones, and a synovial capsule filled with fluid.

The shoulder is a more complicated ball and socket joint, and it is even more complicated than this diagram. The socket is made of several bones and is not as deep as the pelvic socket. We see tendons that go around the head of the humerus, anchoring the top of the biceps muscle into the joint. The muscles are anchored in just the right places to give us maximum mechanical advantage. There are additional layers of muscle and tendon that form something called the **rotator cuff**, which helps to keep the head of the humerus in place. It was not possible to show the rotator cuff in this diagram. (Notice that we see another cartilaginous joint, also, where the acromion is joined to the clavicle.)

There are three kinds of joints: 1) FIBROUS, 2) CARTILAGINOUS, 3) SYNOVIAL

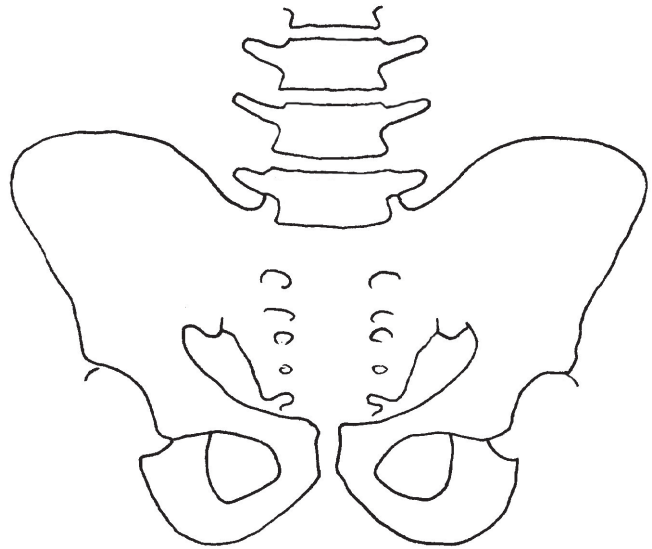
FIBROUS: (don't move at all)

Ex: sutures in skull, teeth in sockets, ends of ulna/radius, tibia/fibula



CARTILAGINOUS: (move only slightly)

Ex: discs between vertebrae, pubic symphysis, ribs/sternum

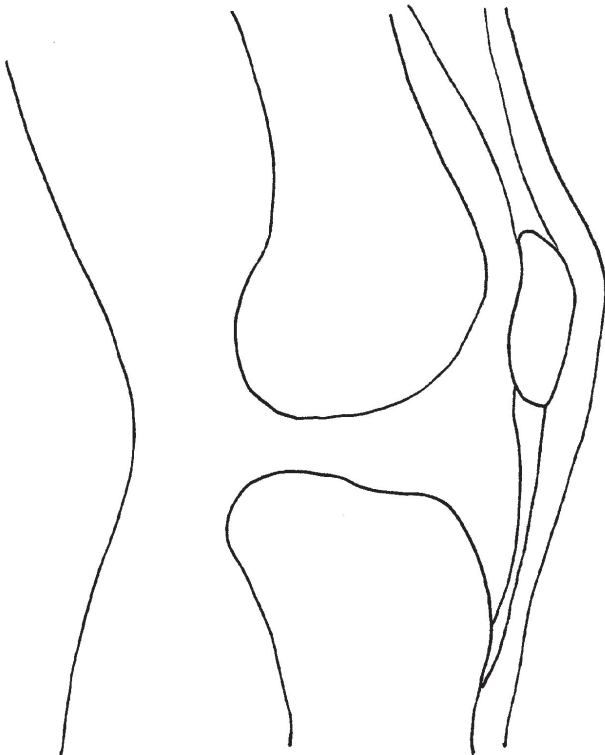


SYNOVIAL: (very flexible)

Synovial joints have fluid-filled capsules in and around the joint to decrease friction. They also have slippery (white) hyaline pads. There are 6 types of synovial joints: hinge, ball and socket, pivot, saddle, plane and ellipsoidal.

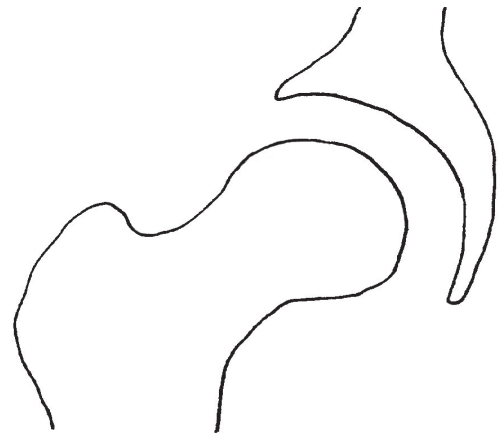HINGE: the knee (shown) and the elbow

- | | | |
|---|---|------------------------------|
| <input type="checkbox"/> hyaline cartilage | <input type="checkbox"/> synovial cavity | <input type="checkbox"/> fat |
| <input type="checkbox"/> ligaments, tendons | <input type="checkbox"/> bursa (fluid filled sac) | |

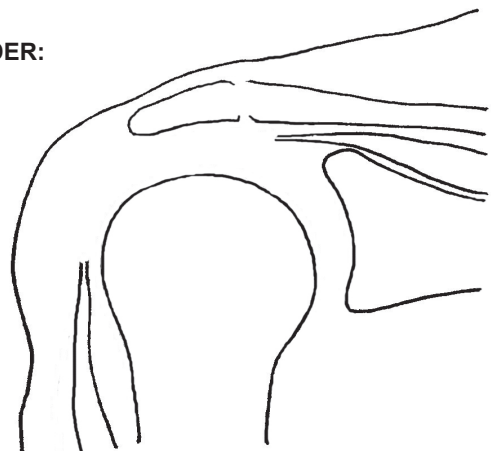


BALL AND SOCKET: hip and shoulder

HIP:



SHOULDER:



78: MUSCLES (as organs)

All muscle cells have these traits in common:

- 1) They are controlled by nerves.
- 2) They contract using actin and myosin. (See lesson 54 for review of actin and myosin.)
- 3) They use cellular respiration as a source of ATP.

There are three types of muscle tissue:

1) **Skeletal muscles** are the ones we control voluntarily to move our body parts. The fibers run parallel in long lines, and they have bands going across them, which are the ends (Z lines) of the sarcomeres. (Remember from lessons 53 and 54 that the sarcomere is the tiny unit that contracts, shortening the muscle. It does so by using little molecular paddles called myosin that push against micro-filaments called actin. You can review those lessons if you can't remember how this works.) Voluntary muscles are made of fibers, not individual cells, and each fiber has many nuclei. It's like many cells merged together, and they all donated their nuclei to the fiber.

2) **Smooth muscles** are involuntary, which means we have no conscious control over them. The cells are spindle-shaped, and are individual cells, each with a nucleus. There aren't any sarcomeres. We are usually unaware of the action of our smooth muscles. Smooth muscles line the digestive tract and cause the churning in the stomach and peristalsis in the intestines. Very tiny smooth muscles surround blood vessels causing constriction or relaxation. Tiny smooth muscles also control the opening and closing of various glands or other micro-structures. Smooth muscles don't operate like skeletal and cardiac. They do have actin and myosin, but they don't have sarcomeres.

3) **Cardiac muscles** are found only in the heart. They are individual cells, but they are connected end to end to form long tubular fibers. The pattern made by these fibers is often described as looking "branched." The fibers have stripes, like skeletal muscles, because they have sarcomeres. The places where the cells connect are called **intercalated discs**. The discs have **gap junctions** made of little "tubes" that allows ions to flow from cell to cell very quickly, carrying an action potential that causes contraction. (You can review gap junctions in lesson 25.) The heart muscles are especially amazing because they get all the rest they need between beats.

Skeletal muscles are made of microscopic muscle fibers. In lesson 53 we saw how muscle fibers are grouped together into bundles. Look back at the top drawing on the lesson 53 page. We drew a neuron traveling along with this bundle and then going down into the bundle to attach to each of the muscle fibers in the bundle. We drew a circle around them and defined this as a motor unit. Motor units are groups of muscle fibers that all work the same way at the same time because they are all stimulated by the same nerve. However, there are millions of motor units in your body, so even with some muscle fibers doing the same thing as their neighbors, your brain still has many options of which ones to combine to be able to move just the way you want to. Think of how amazing it is for your brain to be able to control your muscles so finely that bodies can do things like get a basketball into a hoop, or dance ballet.

Muscles can only do one thing: contract (get shorter). Because of this, muscles must work in pairs. We see this most clearly in skeletal muscles. The muscle that is contracting is called the **prime mover**. The muscle that pulls the other way is called the **antagonist**. The example most often given is the relationship between the biceps and triceps muscles. The biceps is the muscle that contracts when you "make a muscle" in your arm. On the back side of your arm you have the triceps muscle, and it pulls the lower arm back again, straightening the arm.

If we consider the motion of a prime mover muscle (ex: biceps), the place where it attaches to the bone that is staying still is called the **origin**. The place where the muscle attaches on the bone that is moving is called the **insertion**. In our biceps example, the origin of the biceps is up inside the shoulder (as we saw in the last lesson) at a point partly on the scapula. The insertion of the biceps is on the radius bone. Think about it-- when you curl your arm to make a muscle, it is your radius/ulna that move, not your humerus. The insertion point is on the bone that moves.

Muscles also work in groups. The biceps muscle isn't the only one pulling when you curl your arm. The other smaller muscles that help out are called the **synergists** (*SIN-er-gists*). ("Syn" means "with.") Synergy means working together. Synergistic muscles are found all over the body, but are especially well studied in the legs and pelvic areas. Having many muscles working together gives the body the ability to move gracefully with a wide range of motions.

Large scale motions, like curling your arm or lifting your leg, can be classified into groups. A movement that decreases the angle of a joint (like curling your biceps) is called **flexion**. A motion that increases the angle is called **extension**. When you move a body part away from the midline of the body, this is called **abduction**. ("Ab" means "away") When you move a body part towards the midline, it is called **adduction**. ("Ad" means "towards.") Rotation is twisting around an axis, like turning your head. You can also rotate a hand or an arm. Circumduction is when you move an arm or leg in a circle, sort of tracing out a cone shape in the air.

Smooth and cardiac muscles get almost all of their energy from cellular respiration, and the ATPs that are made by the electron transport chain in the mitochondria. (If you need to review, you can go back to lesson 20.) Cardiac muscles prefer to burn fatty acids (not glucose) in their Krebs cycles, but smooth muscles almost always use glucose. Skeletal muscles only use ATPs from cellular respiration after their reserve of **creatine phosphate** is gone. Creatine is a molecule similar to ATP. It can hold onto a phosphate. When the phosphate pops off, energy is released. While creatine is holding a phosphate, it is called creatine phosphate, then after the P pops off, it is called just creatine. Creatine molecules are made in the liver and kidneys, then transported through the blood into the muscles. Muscles have enough creatine phosphate stored up to provide energy for about 8 seconds. After 8 seconds, the muscle will begin relying on the electron transport chains in the mitochondria to provide ATPs. As long as there is enough oxygen in the cells, the ETC will keep making ATPs. If exercise is intense and the lungs can't keep up the supply of oxygen, muscles will begin burning pyruvates and making them into lactic acid. When lactic acid is present, the muscle will feel a burning sensation. Once the exercise stops, the muscles begin clearing out the lactic acid and it is gone in a few minutes. The soreness you feel the day after exercise is NOT from lactic acid, as many people believe. Lactic acid is broken down fairly quickly. Soreness is more likely due to inflammation in tissues.

MUSCLES (as organs)

78

There are 3 kinds of muscles: 1) SKELETAL (voluntary), 2) SMOOTH (involuntary), 3) CARDIAC (heart)

SKELETAL:



- 1) _____
- 2) _____
- 3) _____
- 4) _____

SMOOTH:



- 1) _____
- 2) _____
- 3) _____
- 4) _____

CARDIAC:



- 1) _____
- 2) _____
- 3) _____
- 4) _____

SKELETAL MUSCLES WORK IN PAIRS

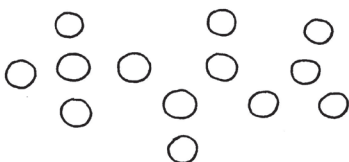
Muscles can only do one thing: CONTRACT.
A prime mover and its antagonist work together.

MOTIONS can be classified

Abduction: body part moves away from midline
Adduction: body part moves toward midline
Extension: joint angle increases
Flexion: joint angle decreases
Rotation: rotates around axis
Circumduction: cone shape is outlined

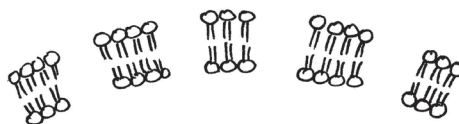
WHERE DO SKELETAL MUSCLES GET THEIR ENERGY? Here they are, in order of preference.

1) CREATINE PHOSPHATE



CREATINE is first choice, but can be sustained for only 8 seconds. Creatine holds onto a phosphate. An enzyme can take the P off, and then put it onto an ADP, making ATP. No oxygen is needed.

2) CELLULAR RESPIRATION (the ETC)



After 8 seconds, cellular respiration kicks in. Oxygen is needed for the Electron Transport Chain to turn ADP back into ATP. Glucose from glycogen is the preferred fuel for the ETC in skeletal muscles.

3) FERMENTATION

Lactic acid fermentation is the third and last choice for energy. This must be used if oxygen is not available. Lactic acid gives that burning sensation in muscles when they are fatigued.

79: THE SKELETAL MUSCLES

Before we start learning the names of the skeletal muscles, we need to do an overview of their functions. Skeletal muscles do more than just move your arms and legs.

Functions of skeletal muscles:

- 1) Make bones move. (the obvious function)
- 2) Make skin move. The muscles in your face allow you to express your emotions and convey feelings to other people.
- 3) Help to maintain a constant body temperature. Contraction of skeletal muscles causes ATP to release energy that causes heat to be produced and helps to warm the body.
- 4) Assists movement in cardiac and lymphatic systems. The pressure of skeletal muscles contraction keeps blood moving in veins (arteries flow because of pumping action of heart), and the lymph fluid moving through the lymph vessels.
- 5) Help to protect internal organs. Bones are covered with muscles, but so are the internal organs. The muscles of our torso help our body to move, but they also cover the stomach and intestines. (You may have seen feats of strength where someone tenses their abdominal muscles so tightly that they can take blows to their torso without any damage to their organs.)

When learning the names of muscles, it helps to understand that the names aren't designed to be difficult, though they often look pretty scary. The names use Latin and Greek word roots which may be unfamiliar to us, but these word roots aren't difficult in their meaning. Common word roots mean things like straight, circular, near, far, triangular, back, front. Easy to understand. Muscle names will always incorporate one or more of these descriptions:

- 1) Size (examples: "maximus" and "major" both mean "biggest")
- 2) Shape (examples: deltoid means shaped like the Greek letter D, which is a triangle, "orb" means "round")
- 3) Location (examples: "frontalis" means "front," "dorsi" means "back," "anterior" means "front," "posterior" means "back.")
- 4) Action (examples: "extensor" means "to extend," "masseter" means "to chew")
- 5) Attachment points (example: the sternocleidomastoid is attached to the sternum, the clavicle, and the mastoid process)
- 6) Number of attachments (example: "bi" means "two" and the "biceps" has two attachment points)

The muscles are all listed on the drawing page, so there is no need to list them all here. Instead, we'll list the word roots that these names use. (Please note that these word roots are not intended for linguistic use. If you happen to be an expert in Latin or Greek, you'll probably be tempted to nit pick about the endings. The only purpose of this list is to help you decode the meaning of anatomy words, not to learn Greek or Latin.)

Abdo: related to the abdomen (stomach area)

Ante: in front

Bi: two

Brachii: arms

Carpus: wrist

Cepes: head

Cleido: related to the clavicle

Cnem: knee

Deltoid: shaped like the Greek letter D (delta)

Digit: fingers

Dors: back

Extensor: action of increasing angle of joint

Ex: outside, or on the outside

Flexor: action of decreasing angle of joint

Gastro: stomach or belly

Glutos: buttocks

Latus: wide or broad

Major: large or important

Masseter: to chew

Musculus: "little mouse" (The Greeks thought the biceps muscle was shaped like a mouse!)

Obliquus: slanting

Occiput: back of skull

Ocu: eye

Orb: round (spherical)

Ori: mouth

Pectoral: related to the chest

Quad: four

Rectus: straight

Sartor: tailor (someone who sews clothes)

Sterno: related to the sternum

Trapezium: "little table" (shape with 4 sides)

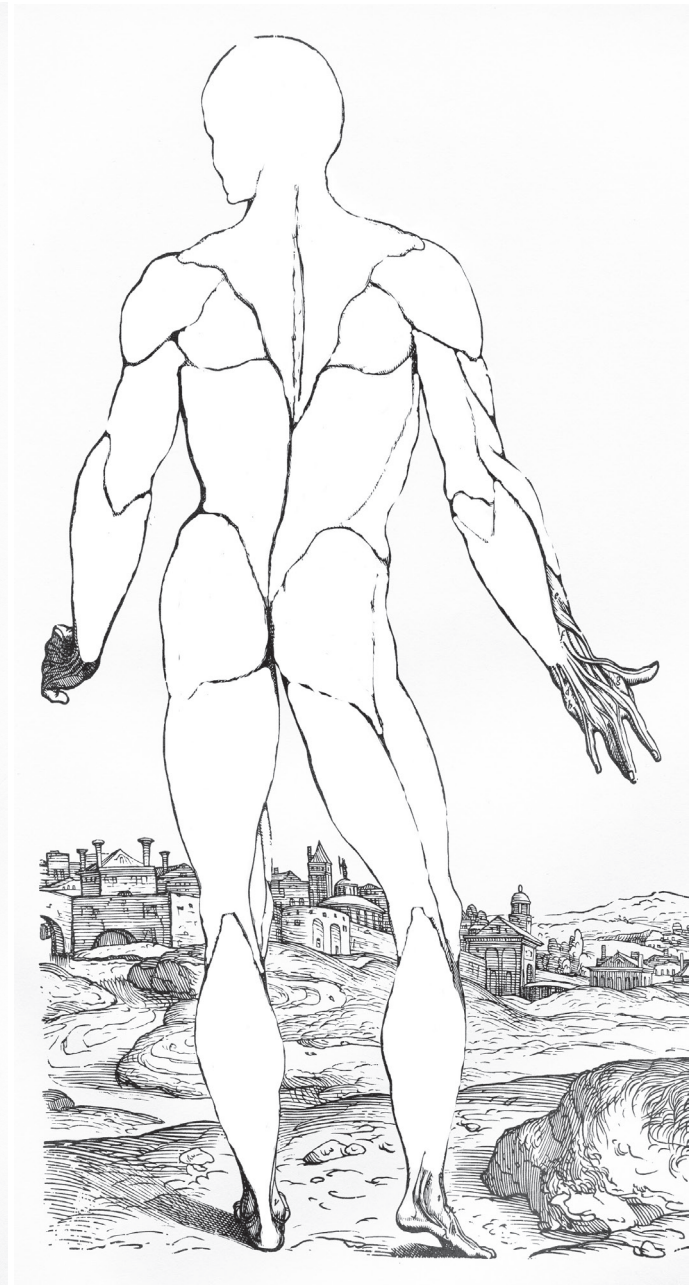Tri: three

Zygomatic: related to the zygomatic arch (cheek bone)

There is one part in our diagram that is not a muscle: the Achilles tendon. It is so large, and so visible in these drawings, that it seemed best to go ahead and label it.

PLEASE NOTE THAT this drawing shows only the major muscles of the body. There are muscles along the spine, for instance, (deep under the back muscles we drew), muscles in the eye (which we saw in the eye drawing), muscles in the groin, and more muscles in the face. There are about 600 individual muscles in the body!

In this lesson, we will be using drawings made by famous anatomist Andreas Vesalius in the year 1555.



HEAD and NECK

- 1) **Frontalis:** wrinkles forehead and moves eyebrows.
- 2) **Orbicularis oculi:** closes eyes
- 3) **Zygomaticus:** smiling
- 4) **Masseter:** closes jaw
- 5) **Orbicularis oris:** closes and protrudes lips (like a kiss)
- 6) **Occipitalis:** moves scalp backwards
- 7) **Sternocleidomastoid:** turns and twists head

UPPER LIMBS

- 8) **Deltoid:** raises arm at shoulder joint ("delts")
- 9) **Triceps brachii:** straightens arm
- 10) **Biceps brachii:** bends arm at elbow
- 11) **Flexor carpi group:** bends hand down at wrist
- 12) **Extensor carpi:** pulls hand up at wrist
- 13) **Flexor digitorum:** closes hand
- 14) **Extensor digitorum:** opens hand

TORSO

- 15) **Trapezius:** moves head, shrugs shoulders ("traps")
- 16) **Pectoralis major:** ("pecs") pulls arm across chest
- 17) **Rectus abdominis:** ("abs") "sit-up" muscles
- 18) **Latissimus dorsi:** ("lats") pulls arm across back and extends shoulders
- 19) **External oblique:** rotates torso
- 20) **Teres major and minor:** pulls arm down and back

LOWER LIMBS

- 21) **Gluteus maximus:** going from sitting to standing
- 22) **Quadriceps group:** straightens leg
- 23) **Hamstring group:** bends leg at knee
- 24) **Sartorius:** rotates thigh (so you can sit cross-legged)
- 25) **Gastrocnemius:** points toes ("calf")
- 26) **Tibialis anterior:** pulls toes up, and inverts foot
- 27) **Achilles tendon**

80: THE ENDOCRINE SYSTEM (an overview)

The endocrine system is the name we give to the major glands of the body. Many of these glands cooperate with each other or with other body parts to keep the body in balance (**homeostasis**).

First, we should review the difference between endocrine glands and exocrine glands. The **exocrine glands** secrete their products into ducts. Exocrine glands include sweat and oil glands, salivary glands, milk glands, and digestive glands in the stomach and intestines. **Endocrine glands** don't have ducts, and secrete their products right into the blood stream. The hormones secreted by endocrine glands act as messengers, carrying instructions to other cells, often cells that are quite far away in a different part of the body.

A **hormone** is a messenger molecule. These messenger molecules can be made of amino acids (**peptide hormones**) or cholesterol (**steroid hormones**). Peptide hormones never enter a cell. Their shape fits into a receptor molecule on the surface of a cell. The peptide molecule fits into the receptor like a key fits into a lock. Once locked in, the receptor causes an ATP to lose 2 phosphates, turning it into a molecule called **cyclic AMP (Adenosine MonoPhosphate)**. "cAMP" is now the new messenger molecule, since the hormone has to stay outside the cell. The hormone molecule will eventually be torn apart and its atoms recycled.

Steroid hormones are nonpolar (hydrophobic) because they have cholesterol as part of their structure. The interior of the plasma membrane is also nonpolar (hydrophobic) and even has cholesterol molecules floating in it. So the steroid hormones have chemistry that gets along well with the interior of the plasma membrane. This means that steroids can just slip right through the membrane, with no channel protein needed. Once inside the cell, they will then bind with some kind of receptor molecule, either in the cytoplasm or inside the nucleus. The final result is that this "complex" (receptor and hormone stuck together) will then bind to a certain place on the DNA and allow that section of DNA to be copied into messenger RNA. The mRNA will then go out of the nucleus and find a ribosome that can translate it into a protein. This takes a while, so the effects of steroid hormones are slower but longer lasting. In contrast, peptide hormones act quickly and strongly.

This lesson will just give a list of the glands in the endocrine system, then we'll go into more detail in the next lessons. Also, some of these glands have been covered in past lessons.

PITUITARY GLAND

This has two parts, the anterior and the posterior. The anterior makes TSH (thyroid stimulating hormone), ACTH (adrenocorticotrophic hormone), FSH (follicle stimulating hormone), LH (luteinizing hormone) and GH (growth hormone). The posterior pituitary makes ADH (antidiuretic hormone) and oxytocin. More on all of these in the next two lessons.

HYPOTHALAMUS

Makes hormones that affect the pituitary gland.

PINEAL GLAND

Makes melatonin, which helps to regulate the sleep/wake cycle (circadian rhythm).

THYROID

Makes T_3 and T_4 for regulating metabolism (how fast the body burns energy), and calcitonin for lowering calcium in blood by decreasing the activity of the osteoclasts (the cells that dissolve bone).

PARATHYROID

This is actually 4 separate spots on the outside of the thyroid. They make PTH (parathyroid hormone) which increases the calcium level in the blood by stimulating the osteoclasts to dissolve more bone.

THYMUS

Trains T cells during childhood. (Lesson 46)

PANCREAS

The Islets of Langerhans make insulin and glucagon that control glucose level in blood. (Lesson 71)

ADRENAL GLANDS

They have two parts: an inner medulla and an outer cortex. The medulla makes epinephrine (adrenalin) and norepinephrine. The cortex makes aldosterone (which affects the kidneys) and cortisol which affects glucose levels and is also anti-inflammatory.

OVARIES and TESTES

Make sex hormones (estrogen, progesterone, and testosterone) that control development in puberty as well as reproduction in adulthood. More on these in future lessons.

THE ENDOCRINE SYSTEM (overview)

80

Endocrine glands secrete hormones into the blood. Hormones are messenger molecules.

PEPTIDE HORMONES are made of _____

STEROID HORMONES are made using _____

Peptide hormones never enter a cell. They bind to external receptors. Usually, ATP is turned into cAMP, which starts a cascade reaction. Cascades allow for rapid manufacturing.

Steroid hormones enter the cell and bind to a receptor inside. That receptor molecule will attach to DNA and cause a certain part to be copied into mRNA, which will then build a protein.

THE ENDOCRINE GLANDS

_____ gland has two parts.

-TSH	-ADH (for kidneys)
-ACTH	-oxytocin (females)
-FSH, LH	
-GH	

_____ makes hormones that affect the pituitary gland.

_____ gland makes melatonin, which helps to regulate sleep cycle.

_____ glands have two parts.

_____ (inside)

- epinephrine (adrenalin)
- norepinephrine

_____ (outside)

- aldosterone (for kidneys)
- cortisol (raises blood glucose, anti-inflammatory)

_____ makes

- insulin (lowers blood glucose)
- glucagon (raises blood glucose) (lesson 71)

_____ gland makes

- T3, T4 for metabolism and growth
- Calcitonin for lowering blood calcium

_____ gland consists of 4 spots on the thyroid. It makes PTH (parathyroid hormone) for taking calcium out of bones and putting it into blood.

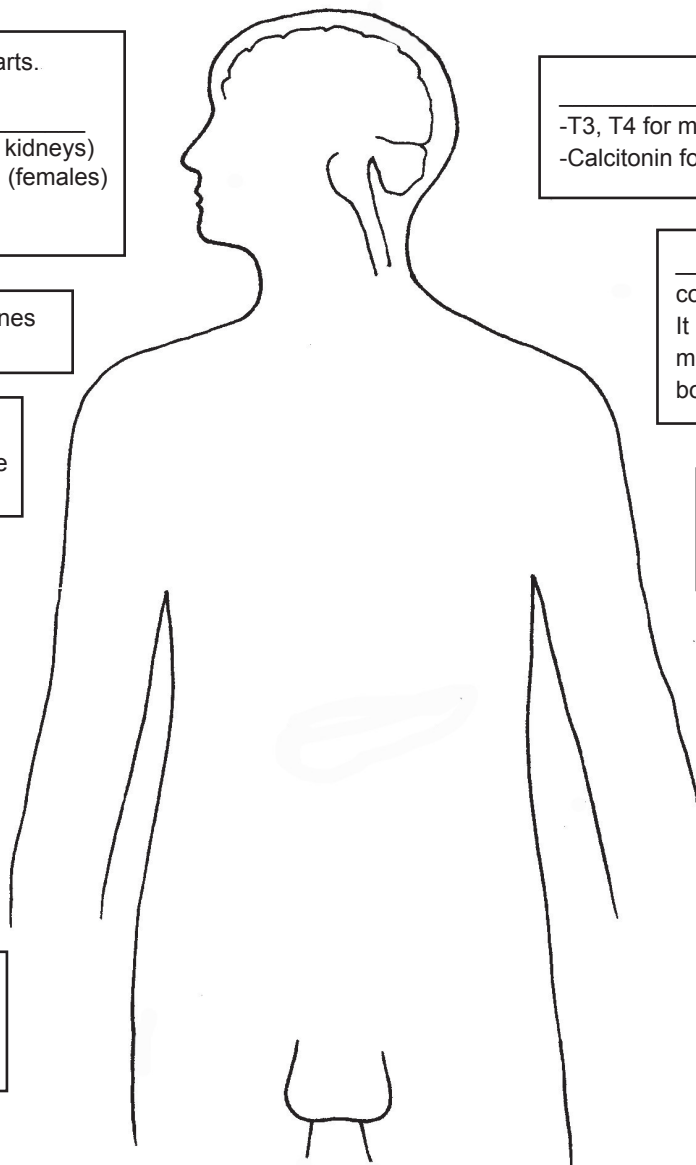
_____ gland is most active during childhood. It trains T cells (lesson 46).

_____ in females

- estrogen
- progesterone

_____ in males

- testosterone



81: HYPOTHALAMUS and PITUITARY

In the next few lessons, we will take a closer look at some of the major endocrine glands. If you find these lessons on the endocrine system confusing, it's not you, it's the endocrine system. Organs such as the hypothalamus and pituitary bring together all of the other body systems in one way or another. That's a guarantee that it's going to be complicated. The main point in this lesson isn't to memorize all this stuff, but to gain an appreciation for how all the body's organs communicate with each other and work together. You'll see lots of information from previous lessons here in this lesson!

The **hypothalamus** isn't a minor brain part. It's the hub where everything comes together. It receives information from both afferent (in-coming) nerves and from the blood. Most of the brain is out-of-touch with the rest of the body because of the Blood Brain Barrier (BBB) which keeps just about everything except food and oxygen from going into brain tissue. However, in the hypothalamus region we find places where that barrier is leaky. Receptor cells in this area need to sample the blood to find out what is currently in it. If there is too much or too little of something, hormone messengers will need to be sent out to correct the imbalance. The hypothalamus uses hormones to control a number of other organs. Often, these correction operations happen automatically, without us needing to do anything. Blood pressure and heart rate go up and down without any thought on our part. Other corrections need us to do something, in order to make the needed adjustment.

The hypothalamus connects our conscious, "thinking" brain to our chemical needs. It receives signals from many sensory cells in the body, so it is informed about things like body temperature, blood pressure, heart rate, level of glucose in the blood, saltiness of the blood, time of day, activity level of the immune system, any many other things. The hypothalamus also has connections to our rational brain-- the parts that control our actions. The behaviors prompted by the hypothalamus are often are things that we "feel like " doing. When our body is hungry we "feel like" eating. When thirsty, we feel like drinking. We might even feel like having one food and not another. If we are very hungry, we may feel grouchy. We can feel like curling up in a blanket, or sitting in front of a fan. The hypothalamus prompts us to act a certain way, in order to maintain homeostasis.

The influence can go the other way around, too, with our behaviors or thoughts affecting our body chemistry. If we are in the midst of sad or upsetting circumstances, our appetite may be affected. Anger can make our blood pressure go up. Scary sights or scary thoughts can make our heart rate go up. When a mother hears her baby cry, the hypothalamus and pituitary can cause the mammary glands to be activated. And so it goes both ways, with our chemistry affecting our behaviors, and our thoughts and behaviors affecting our body chemistry. The hypothalamus is right at the crossroads, where all this back and forth communication takes place.

The **pituitary** is almost like an extension of the hypothalamus. It hangs below it, connected by a thin "stalk." (In lesson 60 we noticed that the pituitary lies inside a protective "pocket" made of bone.) The pituitary has extensive networks of capillaries so it is well connected to the blood stream. Some hormones, like adrenalin, will need to go into the blood very quickly. Specialized neurons (called neuroendocrine cells) reach down from the hypothalamus into the pituitary and direct all its functions.

The pituitary is divided into two parts: the front part (**anterior**) and the back part (**posterior**). Their functions are completely separate, so we will discuss them separately, as though they are two different glands.

The **anterior pituitary** makes peptide hormones that affect many other glands and organs. It's stunning how much it controls, considering that it is only the size of a very small pea. It makes:

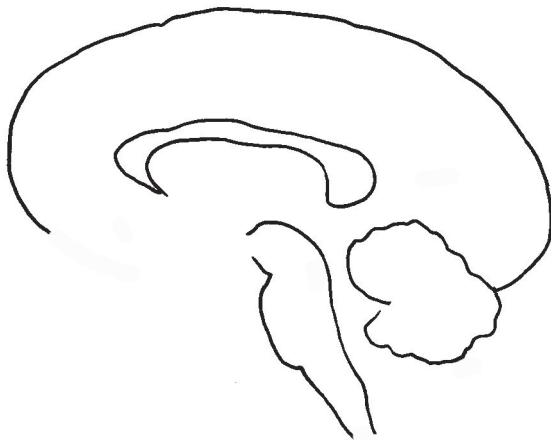- **ACTH (adrenocorticotropic hormone)** which affects the adrenal glands. (More about this in a future lesson.)
- **TSH (thyroid stimulating hormone)** that tells the thyroid to secrete its hormones. (More about this in a future lesson.)
- **GH (growth hormone)** which does more than just make children get taller. Adults still need growth hormone because it also stimulates the immune system, helps bones to stay strong, affects how the liver processes glucose, helps to maintain the Islets of Langerhans in the pancreas, affects the thyroid's hormones to function properly, helps us build muscle, promotes the breakdown of fats, and more.
- **PROLACTIN**, which causes female mammary glands to produce milk. ("Pro" means "for," and "lact" means "milk.")
- **LH (luteinizing hormone)** which makes the testes secrete testosterone and the ovaries secrete estrogen. Release of eggs (ovulation) in the ovaries is caused by a sudden increase in LH. (More on this in a future lesson.)
- **FSH (follicle stimulating hormone)** causes eggs to mature and sperm to be produced. (More about this in a future lesson.)

The **posterior pituitary** makes these peptide hormones:

- **ADH (antidiuretic hormone)** which affects the kidneys. ADH molecules stick to receptors in cells in the collecting ducts in the medulla of the kidneys and cause these cells to put more aquaporin channels onto the inner sides of their membranes (the sides that form the inside lining of the duct). This increase in aquaporins allows more water to go out of the ducts and back into the kidney tissue. Basically, water gets recycled a lot more, and less urine is produced. AND, since the signals are being sent out by a part of the brain that is also in contact with the pineal gland (keeping track of night and day) and the thalamus (one of the parts that regulates consciousness), extra ADH is secreted while you are sleeping so that you makes less urine and hopefully don't need to get up in the middle of the night to go to the bathroom (at least not too often).
- **OXYTOCIN** which affects the smooth muscles in both male and female reproductive organs. (More on this in future lessons.)

Review of location of hypothalamus and pituitary

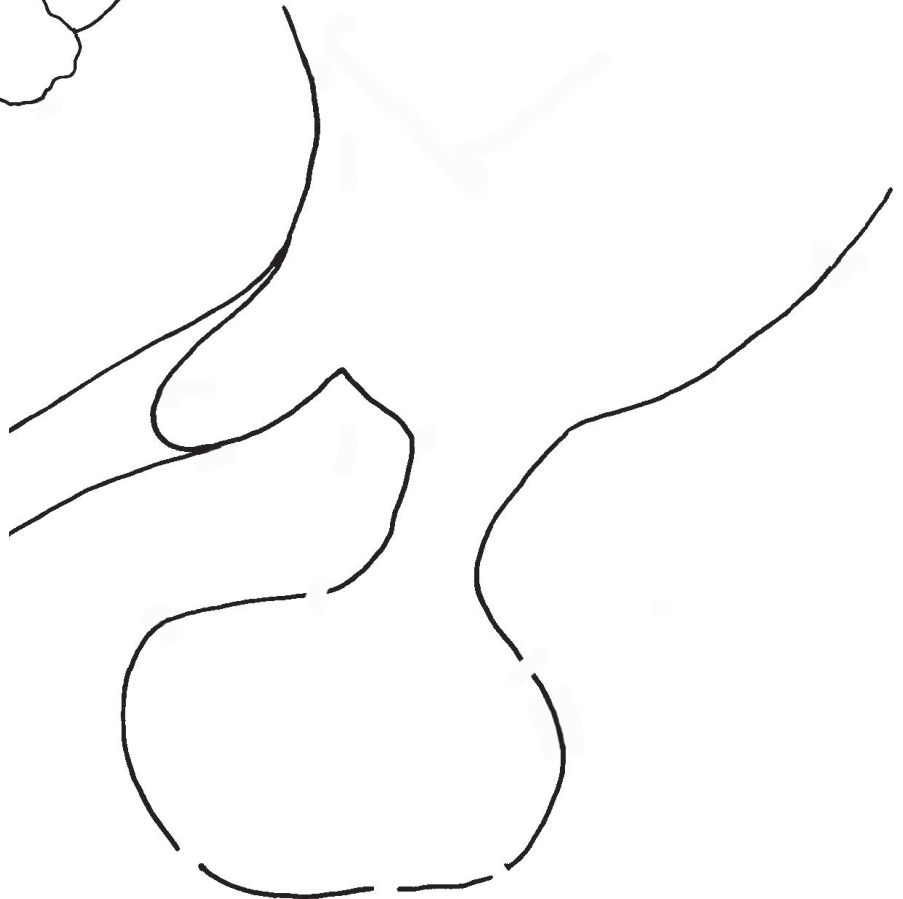The **HYPOTHALAMUS** is a very important control center. It receives input, from both the senses (afferent nerves), and from the conscious mind. It also samples the blood to find out if there is too much or too little of various chemicals.



"ANT-ERIOR" (front)

6 major hormones

- 1)
- 2)
- 3)
- 4)
- 5)
- 6)




The hypothalamus also has a direct connection to the adrenal medulla.

1) ADH sticks to receptors in cells that form the collection tubes at the end of the nephrons.

2) When ADH sticks to a receptor, cAMP is formed (see lesson 80)

3) cAMP triggers the release of aquaporins that are in storage. and they go and embed themselves along the side that faces the lumen (inside) of the tube.

4) Water flows back into tissues and is conserved (less urine).



How ADH works in kidneys

POSTERIOR (back)

Your "posterior" (gluteus) has 2 parts.
(Go ahead and giggle, but you'll remember!)

- 1)
- 2)

82: THYROID and PARATHYROID

The **thyroid** is the main gland in your throat. It is butterfly-shaped and wraps around your trachea. The thyroid is told what to do by the pituitary gland (which, in turn, is regulated by the hypothalamus). When stimulated by TSH from the pituitary, the thyroid secretes three hormones:

- **Calcitonin**
- **T3** (triiodothyronine)
- **T4** (thyroxine)

Calcitonin inhibits (stops) the osteoclasts in bone tissue from tearing it apart. (Remember, osteoclasts are those little macrophage-like cells that are constantly dissolving bone matrix. The osteoblasts built it back up again.) When osteoclasts are very busy, a lot of calcium and other minerals are released into the blood. By slowing down the osteoclasts, calcitonin helps to reduce levels of calcium in the blood.

Thyroid tissue is filled with tiny **follicles** (sacs) that make T3 and T4. (Sometimes you will see these written as T_3 and T_4 .) These molecules are very similar, and body cells can often turn T4 into T3. They are both made of the amino acid tyrosine with some iodine atoms attached. The membranes of the follicle cells have special portals that bring in iodine ions from the blood. If a person's diet doesn't contain enough iodine, the follicle cells will not be able to manufacture the T3 and T4 molecules, which will create a deficiency disease. (Iodine is very compatible with salt molecules, so you will often see "iodized salt" sold as table salt.) After the T3 and T4 molecules are made, they are exported outside the cell into the blood stream, where most of them will latch onto a globulin protein taxi. Over 99% of these thyroid hormones will attach to a taxi, and only a very small amount will end up floating around freely in the blood. (The "free" T3 and T4 molecules are usually what doctors test for when they check your thyroid hormones.) There is a purpose behind having so many of them bound to a taxi. As long as they are bound, they can't do anything, which is good because you don't want too much of these hormones in your blood. If the body suddenly needs more of either T3 or T4, they can be taken off the taxis and used. So the globulins act as a storage mechanism for these hormones, keeping a steady supply handy in a safe way.

One of these protein taxis, TTR, or **transthyretin** is worth mentioning because it might play a role in Alzheimer's Disease. The "retin" part is for "retinol" which is basically vitamin A. This taxi also appears to be able to carry waste proteins called amyloids. If the TTR protein gets folded wrong when it is made, it won't be able to carry away these waste proteins and they will build up in body tissues. In the brain they may contribute to the symptoms of Alzheimer's. We don't completely understand this disease yet, and there may be other causes, but studies have shown that people with Alzheimer's have reduced levels of TTR in both their blood and their cerebrospinal fluid.

Many body cells use T3 and T4. The list of what these hormones help with is quite impressive, and includes helping children to grow, regulating our heart rate and breathing rate, making our appetite function properly, helping our intestines to absorb nutrients, increasing the action of the mitochondria (which helps to generate body heat), regulating the sleep cycle, regulating the amount of cholesterol in the blood, promoting normal function of the reproductive organs, and telling our bodies whether to store fat or burn it for energy.

The **parathyroid** is actually a collection of "dots" on either side of the thyroid, two on each side. The function of the parathyroid is to make the antagonist to calcitonin, which is simply called **PTH (parathyroid hormone)**. This hormone stimulates those osteoclast cells and tells them to be more active in their destruction of bone tissue. This will release more calcium into the blood.

Just like muscles work in pairs, with an agonist and an antagonist, hormones also work in pairs. For most body process, you need both a stimulator and an inhibitor. Another agonist/antagonist pair that we know already is insulin/glucagon.

Calcitonin and parathyroid hormone work opposite each other, to keep the level of calcium in the blood steady. This process is classified as a negative feedback loop. This means that when the level of something drops, this low level triggers a process that will bring it back up. A high level of calcium will be detected by the thyroid and will trigger the release of calcitonin which will cause the bones to absorb more calcium from the blood. When the level of calcium falls, this triggers the release of PTH from the parathyroid, and osteoclasts begin to break down bone and release calcium into the blood. PTH not only causes osteoclasts to work harder, it also causes the kidneys to reabsorb calcium that might otherwise have gone out as waste, and causes the intestines to absorb more calcium from your food. Vitamin D plays a role in calcium absorption so the kidneys also activate vitamin D.

As an interesting side note, the thyroid begins to develop in an embryo when it is only 3-4 weeks old, before the face has really developed, and before the fingers and toes. By the time the fetus is 5 months old, its hypothalamus, pituitary and thyroid are completely functional and levels of all these hormones can be measured. T3 and T4 play an important role in fetal brain development, and also continuing brain development during infancy.

The thyroid and parathyroid control the level of calcium ions in the blood.
The thyroid also makes hormones that affect the health of all body cells.

The **thyroid** makes:

1) _____
which inhibits osteoclasts, stopping
them from dissolving bone

2) _____

3) _____

Both of these affect many body cells
and help with normal functioning of:

The **parathyroid** makes: _____

This hormone acts opposite calcitonin
and raises blood calcium levels by:

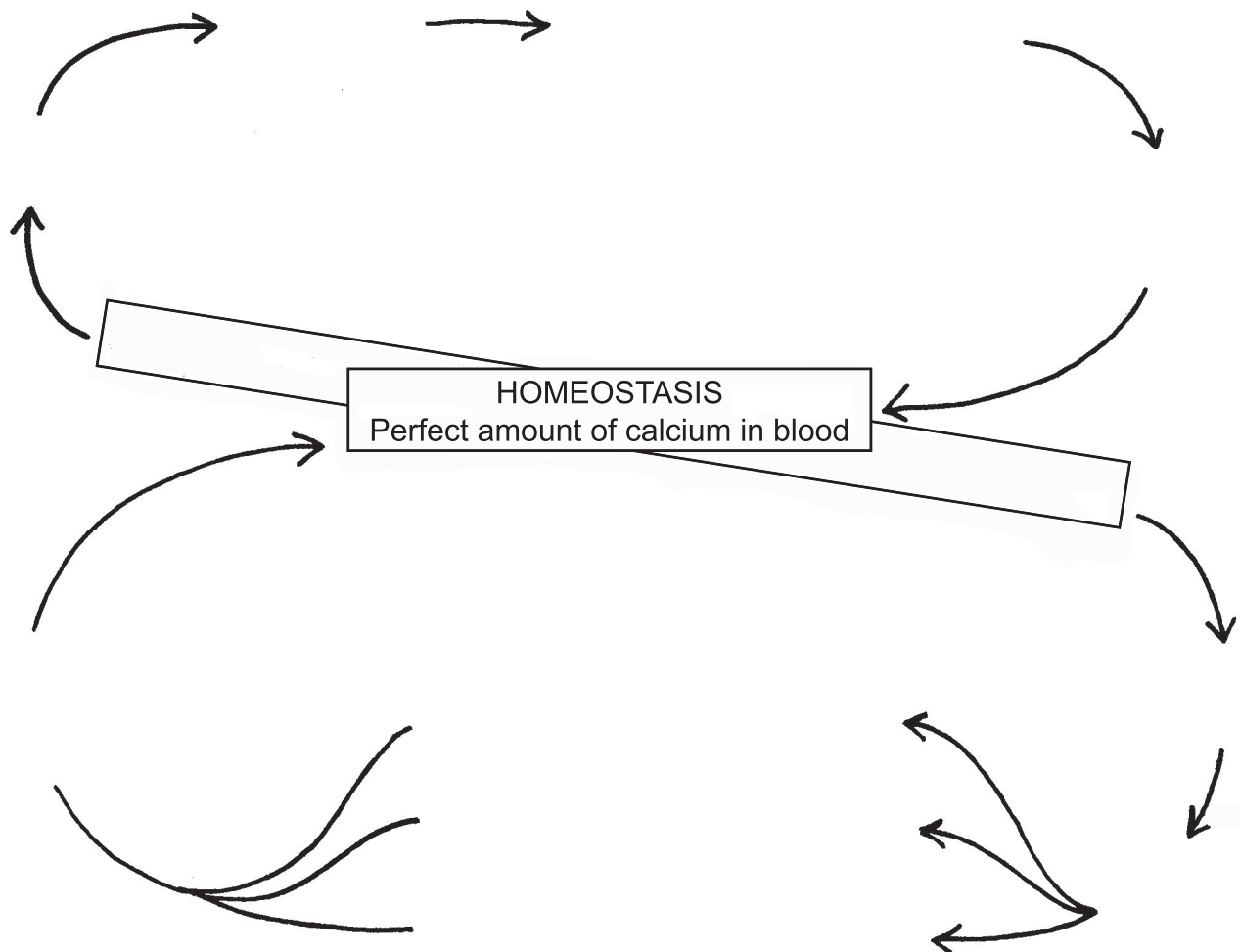
1)

2)



Over 99% of T3 and T4 ride around in globulin taxis. While bound to a taxi, they are inactive. This provides safe storage.

NEGATIVE FEEDBACK LOOPS are the body's way of maintaining homeostasis



83: ADRENAL GLANDS

The adrenal glands are all about dealing with stress. The two sections of the adrenals, the medulla (inside) and the cortex (outside) deal with immediate stress (medulla) and long-term stress. (cortex)

The **adrenal medulla** responds to immediate stress, sometimes so immediate that the response has to happen within seconds. Think of emergency situations where you need to act FAST. It could be something simple and not really all that dangerous, or it could be a situation that is life-threatening. Let's think of something very unlikely, such as being face to face with a tiger. When facing a tiger, what does your body need to do? Be fast enough to run away? Be strong enough to kill the tiger? Your options probably all center on thinking fast, running fast, and being extra strong. In a Marvel comic world, we'd be able to tap into our super powers. Since that's not actually an option, our body does the best that it can at being super. Our heart starts beating faster and stronger, our muscles stiffen, our jaw tightens, our pupils get larger, and our brain begins thinking quickly. We are ready to either fight or take flight. The adrenal medulla (along with some special nerve cells) gives us this "**fight or flight**" response.

The medulla is wired directly to the hypothalamus in order to achieve a very fast response. In only a second or two, our frontal lobe processes what we are seeing and hearing, figures out there is danger, sends a signal to the amygdala, which then sends a signal to the hypothalamus. The hypothalamus tells the medulla to release a hormone you've certainly heard of: **adrenaline**. What you may not have heard of is the other name for adrenaline: **epinephrine** (*ep-in-EFF-rin*). (Unfortunately, you have to learn both words because they get used equally.) The adrenal glands have a large capillary network inside of them, and they are located in an area where the blood flows along pretty quickly, so only seconds after the adrenaline is released into the blood, it is reaching body cells and causing its effects. Adrenaline speeds up the heart, constricts blood vessels in order to increase blood pressure, dilates the pupils, relaxes the bronchioles in the lungs for better oxygen intake, prepares blood for fast clotting, and causes the liver to break down glycogen, putting lots of glucose into the blood. As the seconds tick by, adrenaline begins to work on other organs: Your salivary glands stop making saliva, your digestive system stops doing peristalsis, and your urinary system stops producing urine.

Along with adrenaline (epinephrine), another "sister" hormone is produced, **noradrenaline (norepinephrine)**. "Nor" means "alongside." So these two chemicals are produced alongside each other and work together doing many of the same things. The difference between these two hormones lies in the details of what kind of membrane receptors they bind to. This level of detail is outside the scope of this curriculum. All you need to know is that adrenaline and noradrenaline (epinephrine and norepinephrine) act to keep the body on red alert, ready for action.

The **adrenal cortex** also deals with stress, but not immediate stress. The endocrine system can take its time getting the signals to the cortex. This kind of stress would include things like having a week of final exams, starting a new job, being sick, moving to a new city, coping with divorce, cleaning up after a hurricane, and so on. In times of long-term stress, the hypothalamus secretes a hormone called **ACTH** (adrenalcorticotropin), which tells the adrenal cortex to secrete **glucocorticoid** hormones. This slower, indirect method of cooperation between the brain and the adrenals is often called the **HPA axis** (**H**ypothalamus, **P**ituitary, **A**drenal).

Cortisol (also called hydrocortisone) is the most important glucocorticoid. Just about every cell in the body has receptors for cortisol. Since it is a steroid hormone, it goes through the plasma membrane and enters the cell. There it finds its receptor and binds to it. What happens will depend on what kind of cell it is. This gets into a lot of extremely complicated biochemistry. In the end, all you need to know is that cortisol's main actions are to reduce inflammation and to raise the level of glucose in the blood. The cortisol molecule is very easy to make, so it is an anti-inflammatory drug used very widely by doctors in a variety of diseases. It can even be injected into a joint to reduce inflammation. The downside to using cortisol is that if you take it for a long time, the adrenals stop producing their own supply, and it can be difficult to get them to function again once you stop taking the cortisol.

But wait, there's more! The adrenal cortex does some other things, too. There are actually three separate "zones" in the cortex. The middle zone makes the cortisol we just discussed. The outer zone makes **mineralocorticoids**. As the name suggests, these hormones have something to do with minerals (meaning sodium, potassium, etc.) The most important hormone in this category is aldosterone.

Aldosterone is essential for sodium balance in the kidneys, salivary glands, sweat glands and colon. These are all places where water can be released or recycled. As we learned in the lesson on the kidneys, water molecules follow salt molecules. By the rules of osmosis, water will always go to places where there is a higher concentration of salts, as if it is trying to even things out and make the salty areas less salty. Control where the salt goes, and you control where the water molecules go. Aldosterone's action is to stimulate the sodium/potassium pumps embedded in the plasma membranes of the cells in the distal tubes and collecting tubes of the nephrons in the kidneys. This means that water will be recycled instead of being turned into urine.

Aldosterone is part of a negative feedback loop that starts with the kidneys sensing low blood pressure. The kidneys then produce **Renin**, a hormone whose job is to activate **Angiotensin**. When you see "angio" think "blood vessels." And "tensin" sounds like "tense." Angiotensin tells the tiny muscles around the vessels to contract and make the vessels smaller. This helps to raise blood pressure. Angiotensin also tells the adrenal cortex to make aldosterone, which we have just discussed. Aldosterone makes the kidneys reabsorb salt and water, and produce less urine. Less urine means more blood which means higher pressure.

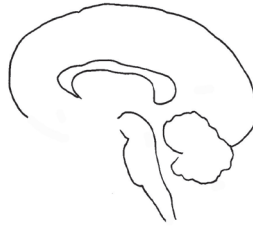When blood pressure gets too high, this is sensed by cells in the atria of the heart, and they secrete **ANH, Atrial Natriuretic Hormone**. ("Natri" refers to sodium, and "uretic" can be thought of as "out with the urine.") ANH inhibits the secretion of Renin and also increases the excretion of salts (sodium) in the urine. Water molecules follow the salts, and thus more urine is produced. Producing more urine helps to lower blood volume, which lowers blood pressure.

Lastly, the inner part of the cortex secretes steroid hormones that can be turned into other hormones. Primarily, it makes **DHEA**, which can be turned into either **testosterone** or **estrogen**. The reproductive organs also secrete these hormones, so we will wait to discuss these hormones until we get to those lessons.

ADRENAL GLANDS

83

The adrenal glands are under the control of the hypothalamus, both directly and indirectly.

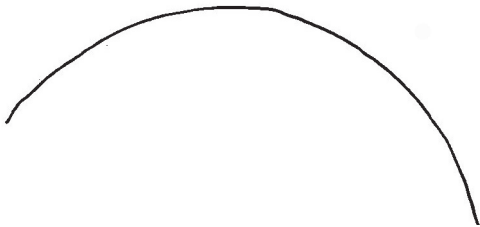



The "HPA axis" is the feedback loop between:

Hypothalamus
Pituitary
Adrenal cortex

In response to stress, the hypothalamus tells the pituitary to secrete ACTH, which acts on the adrenals to make them secrete cortisol.

CROSS SECTION:



MEDULLA hormones deal with immediate stress:

1) _____ aka _____

2) _____ aka _____

Effects:

Heart _____ Vessels _____

Bronchioles _____ Pupils _____

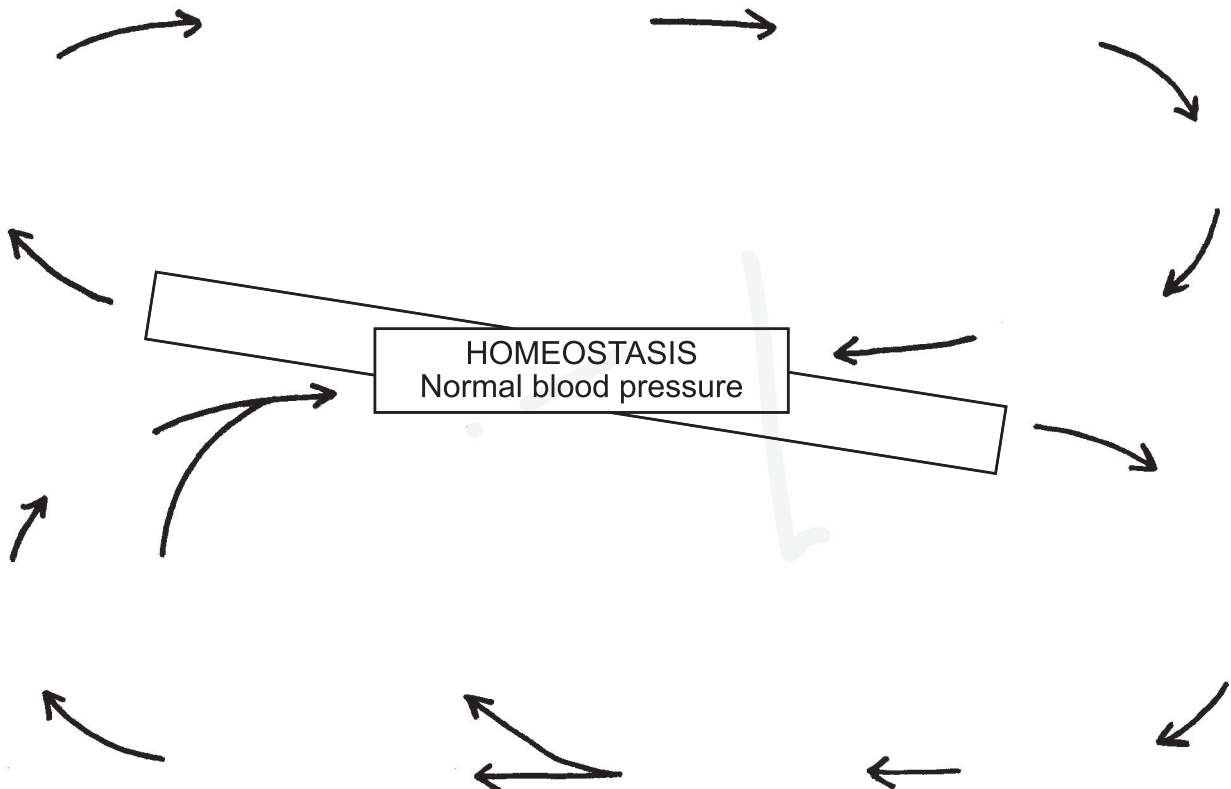
Glucose level in blood goes _____

_____ get ready in the blood.

Slowing down of: _____, _____, and _____

RECOVERY: In 30- 60 minutes the body will have gotten rid of all the adrenaline and noradrenaline molecules.

ANOTHER NEGATIVE FEEDBACK LOOP:



84: AUTONOMIC NERVOUS SYSTEM

The autonomic nervous system is part of the peripheral nervous system, meaning it lies outside of the central nervous system (brain and spinal cord). The word "autonomic" might remind you of the word "automatic," and this is a correct association to make. The autonomic nervous system (ANS) does function automatically, without us giving any conscious thought to it. The main controller of the ANS is a part we just looked at just recently: the hypothalamus. The ANS includes all the millions of tiny nerves that go into smooth muscles, cardiac muscles, and glands. The ANS is the controller of bodily functions such as heart rate, digestion, breathing, sweating, shivering, salivation, urination, and reflexes such as sneezing, coughing and vomiting. Although this system is automatic, we saw in the last lesson that it does still have a connection to the conscious brain and the voluntary systems.

The autonomic nervous system has basically two parts, although some people like to add a third. Traditionally, the ANS was always divided into the **sympathetic system**, and the **parasympathetic system**. Recently, some like to classify the nerves going to the digestive system as the **enteric system**. We'll stick to tradition and just talk about the sympathetic and parasympathetic. Also, this will not be an exhaustive list of everything each system does, just a mention of the more obvious functions.

The sympathetic system is the part that does the "fight or flight" response we learned about in the last lesson. The sympathetic system gears you up and makes you ready for action. Your heart rate and breathing rate increase, your pupils dilate, your liver releases glucose, and all your digestive processes from salivation to urination are inhibited. We discussed this in lesson 83. All the nerves of the sympathetic system go out from the thoracic and lumbar areas of the spine (the part inside the thoracic and lumbar vertebrae).

The parasympathetic system does just the opposite. The parasympathetic calms you down. It slows your heart rate, calms your breathing, constricts your pupils, and stimulates your digestive system. The parasympathetic is your "rest and digest" system. All the nerves of the parasympathetic system go out either from the top of the spine, or from the very bottom (sacral area). The ones at the top are part of a group of nerves we call the **cranial nerves** (because they come out of the bottom of the cranium). A very special cranial nerve called the **vagus nerve** drops down and branches off into all the organs. We saw the vagus nerve going to the stomach in lesson 70. When a nerve goes into an organ we say that it "innervates" it. (The "nerve" goes "in.")

Each impulse sent out by the ANS requires only two neurons. The place where they meet is called the **ganglion**. (In our drawing we keep track of which way the nerve is pointing by drawing the cell body as a dot and the axon terminal as a tiny "C" curve.) In the sympathetic system, the nerves go from the spinal cord into a nerve ganglion cord that runs parallel to the spine. Nerves that go from the CNS to a ganglion are called the "pre-synaptic" nerves. Nerves that run from the ganglion to the organ are called the "post-synaptic" nerves. The post-synaptic nerves in the parasympathetic system tend to be very short, and can even be entirely inside the organ. In the sympathetic system the post-synaptic nerves are much longer. (NOTE: None of distances between the neurons in our drawing are very accurate. This is just a rough idea of how they are arranged.)

Although we think of these systems as turning on and off as we respond to strong stimuli in our environment, the truth is that both systems are constantly active at a low level. The digestive organs need to be stimulated. Dilation and constriction of the pupils goes on all the time as our eyes adjust to the level of light around us. Our heart may need to be stronger and faster just because we get up out of a chair and begin to walk, not because we are facing danger. Sometimes the balance changes dramatically, such as when we face danger, or when we are trying to fall asleep, but both are always functioning to some degree.

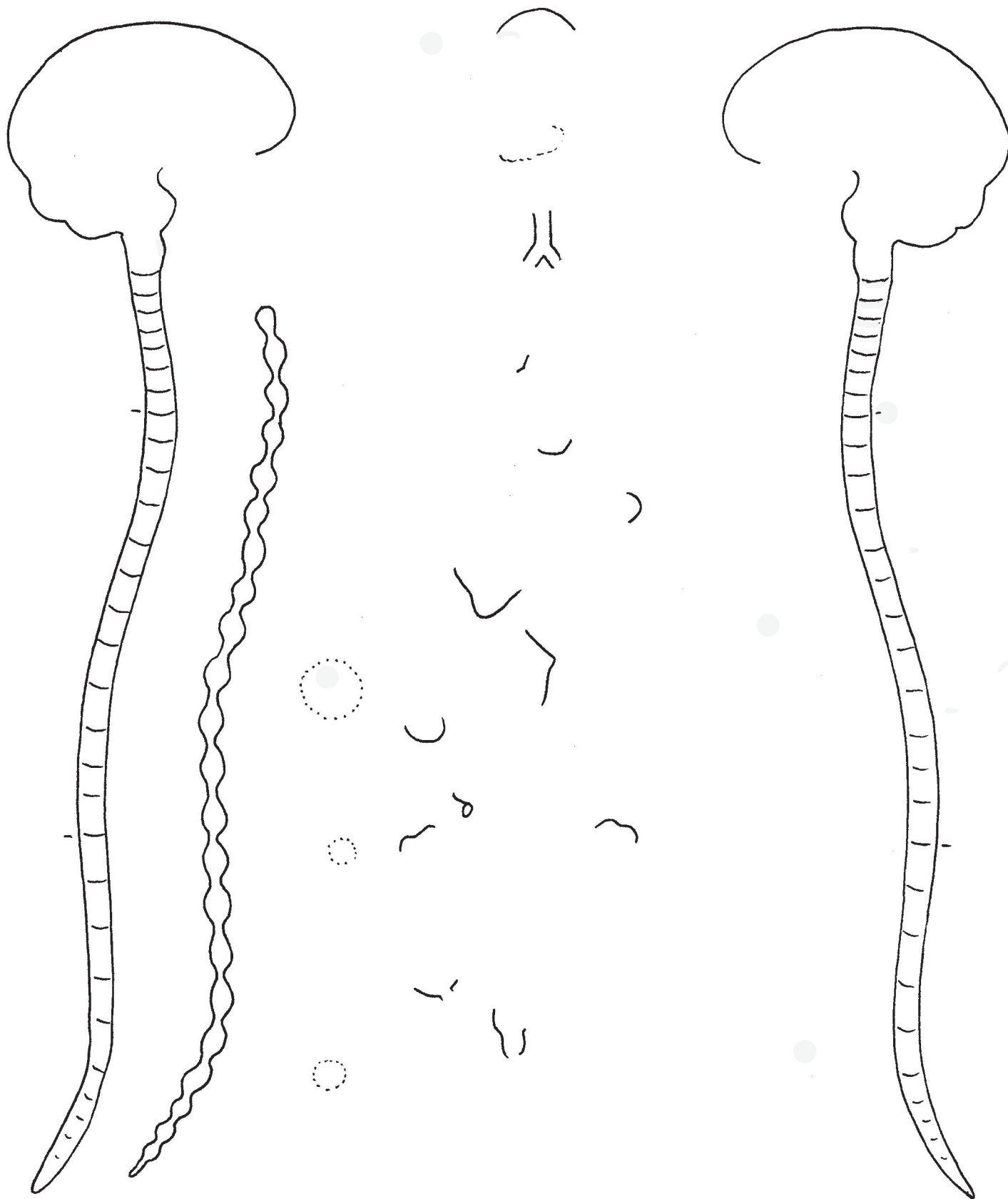
AUTONOMIC NERVOUS SYSTEM

84

The autonomic nervous system (ANS) is part of the peripheral nervous system (PNS) and functions automatically. Each stimulus travels a route that is made of only 2 neurons.

SYMPATHETIC

PARASYMPATHETIC



85: MALE REPRODUCTIVE SYSTEM

Mammalian reproductive systems are marvels of engineering. In this lesson we will see how each part is located in exactly the right place, maximizing its efficiency. In other words, if these parts were in a different order, the system would not work. Speaking of efficiency, the male reproductive system "borrows" some parts from the urinary system. Why have an entirely separate system when you can reuse the same parts for a different purpose? Here are the parts classified by which system(s) they belong to:

Urinary only: bladder, ureter

Both urinary and reproductive: urethra, penis

Reproductive only: testes, epididymis, vas deferens, prostate, seminal vesicle, bulbourethral gland (a.k.a. Cowper's gland)

Let's start with the **testes**. (Singular is "testis.") The testis is the oval-shaped thing inside the **testicle**. The word testicle generally refers to the testis and also the things that surround it, like the epididymis and the outer covering of skin. (The outer covering is called the **scrotum**. This is a Latin word, possibly meaning "a leather bag." The word scrotum usually refers to both testicles.) The testis is where the sperm are produced. Remember that we started out saying that everything is the right location? Turns out there is a reason for the testis being outside of the body, instead of hidden inside like the female ovaries. Sperm need to be kept a little cooler than body temperature. At a certain point in fetal development, the testes begin to move to the outside of the body. If this process does not happen, babies will be born with "undescended testicles" and will need to have surgery to bring them outside. Without this surgery, the boy will likely not be able to father children when he grows up because the testes will be too warm all the time.

Inside the testis we find lobes that are filled with coiled tubes. These tubes are called **seminiferous tubules**. If we look at a cross section of these tubes, we find an organized arrangement of cells. The circle around the outside of the tube is the basal lamina, a tissue we've seen in other places, associated with epithelial cells. Just inside this circle, around the outer edge, we find stem cells called **spermatogonia**. Amazingly, these cells came into being when the fetus was just 4 weeks old! They migrated to these tubes once the tubes were formed. The spermatogonia divide constantly, starting at puberty and continuing on throughout the man's lifetime. One "daughter" cell will become the new stem cell, and the other will become a **primary spermatocyte**. The primary spermatocyte then goes through meiosis, meaning that its two "daughter" cells will have only half the original amount of DNA. Normal cells have two sets of chromosomes and are called 2N. After the first step of meiosis, each cell will have only one set of chromosomes, N. (A cell with N chromosomes can also be called "haploid.") These N cells are called **secondary spermatocytes**. Each of these N cells splits in half to produce a **spermatid**. This division process is more like mitosis because the chromosome count stays the same, and the spermatids are still N. The spermatids will then turn into **sperm** (also known as **spermatozoa**), as they develop acrosomes and flagella. (Thousands are produced every second!) This maturation process takes over two months from start to finish. And, even more amazing, the sperm do not become fully **motile** (able to move) until they are already inside a female reproductive system. The female system provides the right environment (the right chemistry) for them to achieve maximum **motility** (motion).

Between all the seminiferous tubules, we find **Leydig cells**, which release the hormone **testosterone**. Testosterone controls masculine body features (large muscles, broad shoulders, hair on face, deep voice) as well as the production of sperm cells. Leydig cells are stimulated into action by the hormone **LH**, secreted by pituitary. The pituitary, in turn, is stimulated by the hypothalamus.

There are supporting cells (**Sertoli cells**) in the seminiferous tubules that nourish the spermatocytes as they develop. They pick up food and oxygen from the circulatory system and pass it along to the spermatogonia and spermatocytes. (This might remind us of the astrocytes that nourish the neurons in the brain, or the pigmented epithelial cells in the retina that nourish the rod and cone cells.) Sertoli cells are controlled by the hormone **FSH**, secreted by the pituitary. (And the pituitary is under the control of the hypothalamus.)

The sperm don't swim in these tubes. A tiny amount of liquid flushes them out into the next structure, the **epididymis**. This is a very long tube that is coiled up around, and on top of, the testis. The epididymis is where the sperm are stored. They don't swim around here, either. They are gradually swept along by ciliated cells that line the tubes. (We saw similar ciliated cells in the trachea sweeping mucus along.) If the sperm are not used, they can be reabsorbed and all their proteins broken down and recycled, just like your body recycles all other dead cells.

From the epididymis the sperm then move into a very long tube called the **vas deferens**. If you follow this tube up and over the bladder you will see that it eventually merges with the **urethra**. This merger happens inside the **prostate gland**. The prostate is a combination of glands and muscles, and has several jobs. The glands make about 30% of the transport fluid, or **semen**, that will carry all the sperm (millions of them). The glands add some interesting things to the semen fluid, like zinc, citric acid, and a protein called Prostate Specific Antigen (PSA) which will help keep the liquid from becoming too thick when other glands add their secretions. The muscles in the prostate do two things: they squeeze shut the entrance to the bladder so that no urine can leak out while sperm are passing through the urethra, and they help to propel the sperm through the urethra and into the penis.

Also at this merger point (where the vas deferens meets the urethra) we see a gland called the **seminal gland**. This gland produces about 60 percent of the semen fluid, and it also adds to the mixture some fructose sugar (energy for the sperm cells), several enzymes, vitamin C, and a hormone called prostaglandin that will help protect the sperm from the female's immune system cells.

Below the prostate gland we see the **bulbourethral gland** (a.k.a. Cowper's gland). Its job is to produce a fluid that will go through the urethra before the sperm-containing semen gets there. This fluid will neutralize any acidity left behind by urine, and will also provide mucus to help the sperm have a smooth ride through the urethra. This gland is just where it needs to be to do its job.

For the semen to be able to be released right near the female uterus, the penis needs to change its shape. This is accomplished by two areas of tissue (best seen in the cross section view) called the **corpus cavernosum**. The autonomic nervous system can cause a release of nitric oxide (NO) in this tissue, which tells the capillaries to expand and allow extra blood to come in. As this area swells, the drainage veins become blocked, so the blood can't get out. After the semen leaves the body through a process called **ejaculation**, the drainage veins open again and the penis goes back to its normal shape. Anywhere from 50 million to 1 billion sperm can be released in one ejaculation.

INTERESTING FACT: The testes produce **thousands** of sperm **per second**.

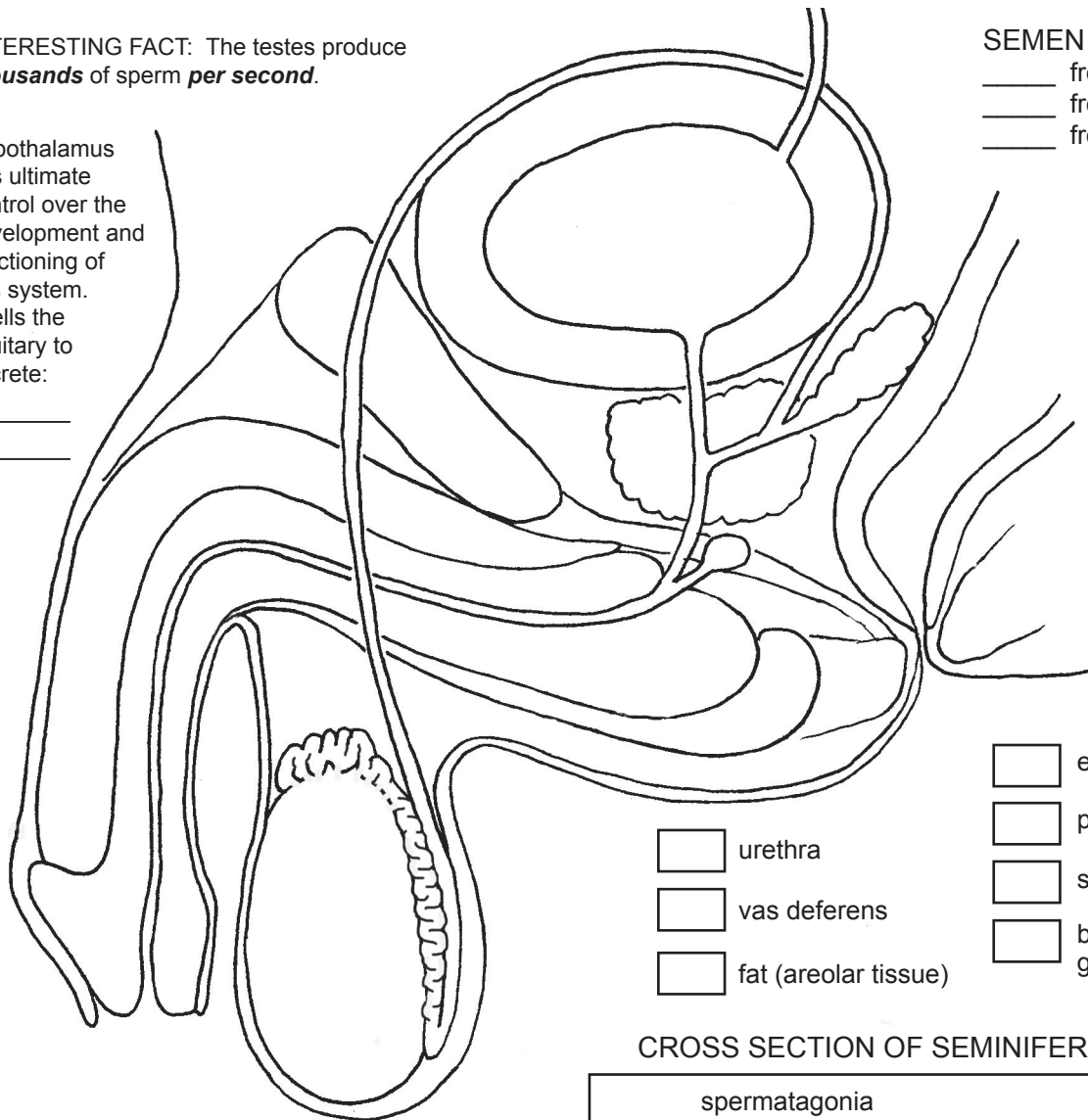
Hypothalamus has ultimate control over the development and functioning of this system. It tells the pituitary to secrete:

- 1) _____
- 2) _____

SEMEN is complicated!

- _____ from prostate
- _____ from sem. vesicle
- _____ from bulbourethral

Contains:



urethra

vas deferens

fat (areolar tissue)

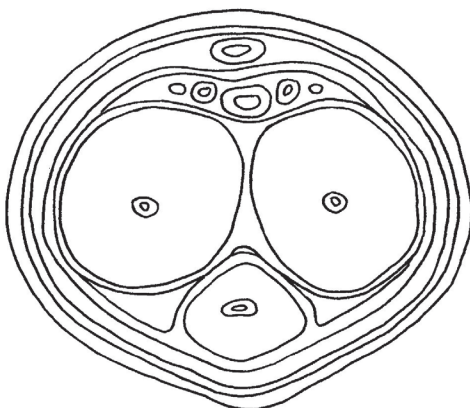
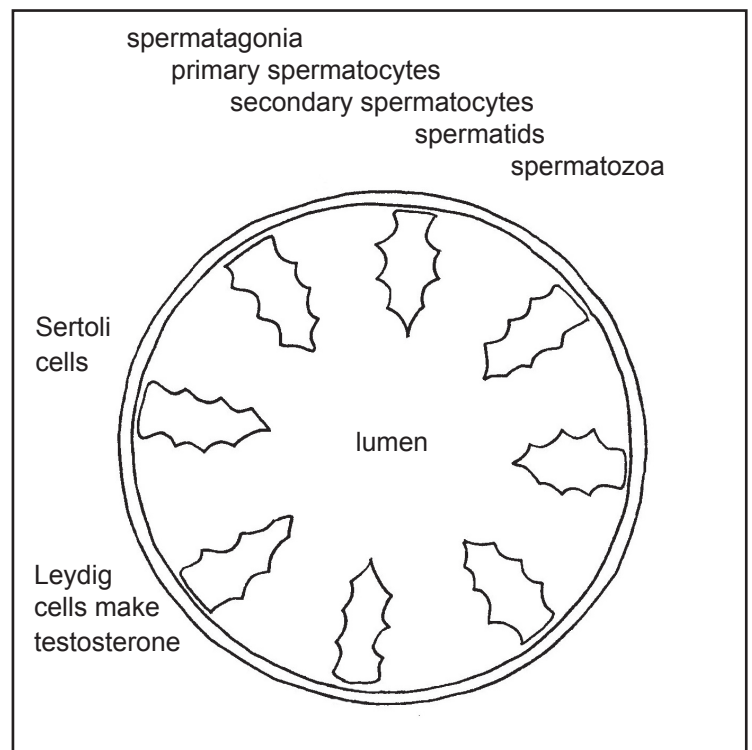
epididymis

prostate

seminal vesicle

bulbourethral gland

CROSS SECTION OF SEMINIFEROUS TUBULE



CROSS SECTION OF PENIS

corpus cavernosum

corpus spongiosum

loose connective tissue

arteries

veins

nerves

fascia "bags"

86: FEMALE REPRODUCTIVE SYSTEM

Though in many ways the female reproductive system is quite different from the male system, we will find a few ways in which they are similar. We will see some of the same hormones operating, and we will see a location where we find similar tissue types.

In the female system, the urinary tract and the reproductive tract are completely separate. The female urethra is very short, only a few centimeters. The bladder is right under the uterus, so when the bladder is full, it pushes the uterus upward. This is handy for ultrasounds when you want to image the uterus. Before an ultrasound, the patient must drink a lot of fluid so that the bladder is as full as possible and will raise the uterus to a more vertical position, giving the technician a better view in the ultrasound image.

The **uterus** (where the baby grows) is a very muscular organ. The muscles must be strong enough to push a baby out during childbirth. The uterus has a delicate lining called the **endometrium**. It is made of tissue that is full of capillaries. The bottom of the uterus is called the **cervix**. The **ovary**, where the eggs (**oocytes**) develop, is outside of the uterus but is anchored to it by a ligament. When eggs are released from the ovaries, they are picked up by the **fimbriae** (finger-like things) at the end of the **oviducts** (which are also called **fallopian tubes**). We saw in module 2 what happens to the egg cell as it travels down the oviducts and into the uterus. If there is sperm present and the egg is fertilized, the tiny embryo will try to implant itself in the wall of the uterus. The tube that leads from the uterus to the outside world is called the **vagina**. (The vagina is often called the **birth canal**.)

The lower parts of the female system are the **labia minora** and **labia majora** (basically "flaps" that cover the openings to the urethra and vagina), and the **clitoris**. The clitoris has an interesting embryonic history, in that the same type of embryonic tissue can produce either a penis or a clitoris. Because of this, we find very similar tissue types in both structures (tissue that can enlarge and fill with blood). The clitoris is the primary organ of sexual pleasure for women, although the vagina does play a minor role, as well.

When females are born they have about a million oocytes ready and waiting in the ovaries. Nothing happens until puberty, when the girl's body starts to produce more estrogen and she begins to develop into a woman. By this time the number of oocytes has dropped to about half a million. (Unused eggs just disintegrate and their proteins can be recycled.)

The oocytes are each wrapped in a layer of protective cells called a **follicle**. Once the young woman begins to have her monthly cycle, each month one of these **primary follicles** will begin to grow and to secrete estrogen and progesterone. First it becomes a **secondary follicle**, then it turns into a **vesicular follicle** that contains a vesicle filled with fluid. This fluid will help the next process take place. At about day 14 of the 28-day cycle, the vesicular follicle touches the wall of the ovary and it bursts out, expelling the oocyte. This is called **ovulation**. The follicle then heals itself and turns into a **corpus luteum**. ("Luteum" means "yellow.") The corpus luteum will continue to produce hormones for a few days, but then will quickly start to get smaller and smaller, and eventually disappear and disintegrate.

If pregnancy were to occur, a hormone produced by the embryo (**HCG**) would prolong the life of the corpus luteum so it would go on producing its hormones, especially progesterone. ("Pro" means "for," and "gest" means "pregnancy.") As long as the corpus luteum is active and producing progesterone, the uterus will not shed its lining. This is important because the embryo needs to connect to the capillaries in the thick endometrial lining. (Eventually, the placenta will take over this role of producing hormones and the corpus luteum will disappear.)

If there is not an embryo present, the corpus luteum will do its normal routine and begin to disintegrate. As it does so, the hormone levels will drop and this will initiate the breakdown of the endometrium. The dying endometrial cells produce an enzyme that will prevent the blood from clotting, so that it will flow out smoothly and easily. Occasionally, if the bleeding is very fast and heavy, the cells will not be able to keep up with the need for the anti-clotting chemicals, and the woman will notice clots in the flow.

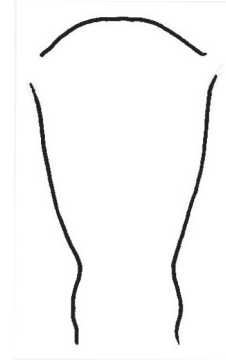
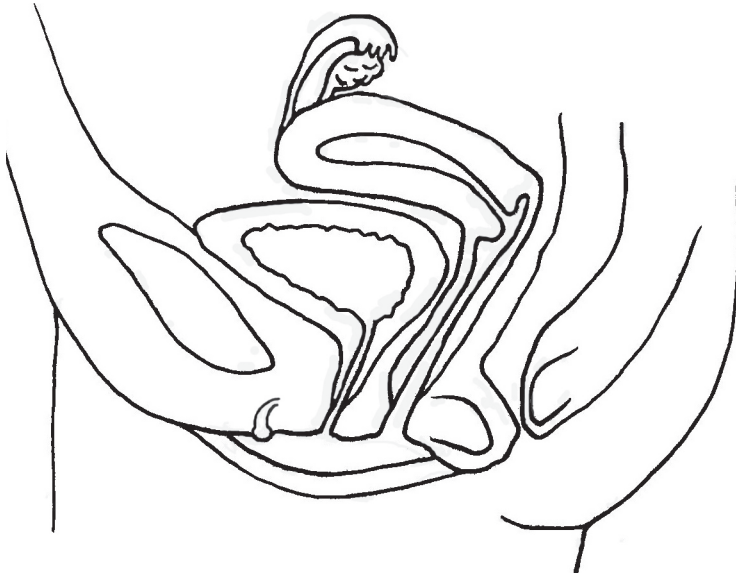There is a feedback system between the ovaries and the pituitary. When the pituitary senses the rising levels of estrogen and progesterone, it will stop making so much FSH and LH. Then, when the levels become low, it will start producing more FSH and LH.

Women's bodies also produce a small amount of testosterone. Male bodies produce a small amount of estrogen. So everyone produces everything, but with gender-specific quantities. When women take a lot of testosterone, or when men take a lot of estrogen, their bodies will slowly begin to change and become more like the opposite gender, but the anatomical parts will not change (although they might be reduced in size a bit, or stop working quite so well). However, there will also be long term damage done to other body systems such as the cardiovascular system (heart and blood vessels), as hormones do affect other body tissues, not just reproductive tissues. After a number of years, these people will start to see many negative effects on their overall health.

When women get into their 40s or 50s, a "clock" in their brain decides that it time to stop ovulating and having menstrual periods. Childbirth is a rigorous experience and older women will experience far more problems than younger women. Also, the eggs have aged for decades and chances go up for having a defective egg be fertilized and produce a baby with severe, or fatal, problems. The pituitary and hypothalamus stop producing the hormones that cause the monthly cycle. Ovulation stops and the woman can no longer become pregnant. This is called menopause.

CROSS SECTION SHOWING ORGANS

FRONT VIEW: UTERUS, OVARIES



- (1) **Primary follicles:** contain an oocyte, and they produce estrogen and progesterone
- (2) Primary follicles get larger and are called **secondary follicles**.
- (3) A secondary follicle turns into a **vesicular follicle** when it becomes filled with fluid and touches the ovary wall.
- (4) The follicle bursts and the oocyte (egg) is released from the ovary. (**ovulation**)
- (5) The follicle turns into a **corpus luteum**, which makes estrogen and progesterone ("pro" means "for," and "gest" means "pregnancy.")
- (6) The corpus luteum disintegrates.

= FSH = LH (pituitary)

= estrogen = progesterone (ovaries)

I N O V A R Y	
I N U T E R U S	