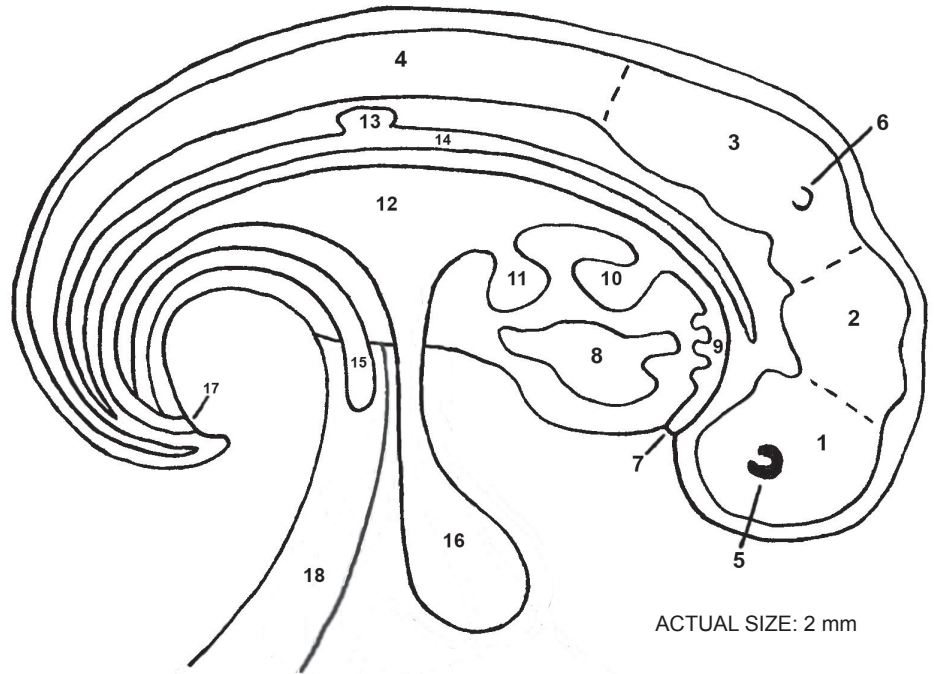


**END OF WEEK 4 (28 DAYS)  
SAGGITAL SECTION**

- 1) \_\_\_\_\_
- 2) \_\_\_\_\_
- 3) \_\_\_\_\_
- 4) \_\_\_\_\_
- 5) \_\_\_\_\_
- 6) \_\_\_\_\_
- 7) \_\_\_\_\_
- 8) \_\_\_\_\_
- 9) \_\_\_\_\_
- 10) \_\_\_\_\_
- 11) \_\_\_\_\_
- 12) \_\_\_\_\_
- 13) \_\_\_\_\_
- 14) \_\_\_\_\_
- 15) \_\_\_\_\_
- 16) \_\_\_\_\_
- 17) \_\_\_\_\_
- 18) \_\_\_\_\_



ACTUAL SIZE: 2 mm

NOTE: This is highly simplified. There are other blood vessels, besides the dorsal aorta, but they are not shown. The heart has large vessels coming out of it. There are also tiny vessels connecting to sacs and cord.

**END OF WEEK 5 (33-35 DAYS) EXTERNAL VIEW**

- 1) \_\_\_\_\_
- 2) \_\_\_\_\_
- 3) \_\_\_\_\_
- 4) \_\_\_\_\_
- 5) \_\_\_\_\_
- 6) \_\_\_\_\_
- 7) \_\_\_\_\_
- 8) \_\_\_\_\_
- 9) \_\_\_\_\_
- 10) \_\_\_\_\_
- 11) \_\_\_\_\_
- 12) \_\_\_\_\_

